

A Case of Mucormycosis Presenting With Total Ophthalmoplegia and Peripheral Facial Palsy

Periferik Yüz Felci ve Total Oftalmoplejiyle Prezente Olan

Mukormikozisli Bir Olgu Sunumu

Ayfer Ertekin¹, Recep Aygöl¹, Gökhan Özdemir¹, Dilcan Kotan², Hızır Ulvi¹

¹ Ataturk University Medicine of Faculty, Department of Neurology, Erzurum

² Sakarya University Medicine of Faculty, Department of Neurology, Sakarya

Özet

Mukormikozis Zigomiçes grubunun mukorales cinsi bir fungusun neden olduğu akut başlayan ve sıklıkla öldürücü bir hastalıktır. Mukormikozis enfeksiyonları nadiren sağlıklı bir konağı enfekte eder, ancak diyabetes mellitus ve immünsüpresif altındaki hastalarda fatal enfeksiyonlara yol açabilir. Göz kapağında düşme, görmede azalma, çift görme, yüz ve baş ağrısı şikayetleriyle kliniğimize başvuran 17 yaşında erkek hastaya, başka bir merkezde astım teşhisi konulmuş ve diyabet öyküsü bilinmeksizin oral ve intravenöz metilprednizolon uygulanmıştı. Nörolojik muayenesinde ılımlı periorbital ödem, sol gözde ptöz, amaroz, total oftalmopleji ve periferik yüz felci mevcuttu. Laboratuvar bulgularında lökositoz ve hiperglisemi dışında özellik yoktu. Magnetik rezonans inceleme ile enfeksiyonun progresse olduğu görüldü. Otuzbirinci günde sert damakta bir palatal ülser tespit edildi. Mukormikozis şüphesiyle damaktan alınan doku örneğinin kültür ve histopatolojik incelemesiyle tanı doğrulanmış oldu. Bu bulgular eşliğinde, yatışının ilk 12 saati içinde acil intravenöz antibiyotik ve antimikotik tedavi başlatıldı. Kaviteyi temizlemek için iki kez cerrahi debridman uygulandı. Bu yoğun tedaviye rağmen hasta kliniğimize yatışının kırkinci günü ex oldu. Bu olguyla, mukormikozisin yüksek mortaliteyle sonuçlanabilen bir hastalık olduğunu vurgulamak istedik.

Anahtar Kelimeler: Mukormikozis, gizli diyabet, immünsüpresyon, periferik fasiyal paraliz, oftalmopleji

Başvuru Tarihi: 25.03.2011 **Kabul Tarihi:** 17.08.2011

Abstract

Mucormycosis is an acute and often fatal infection caused by a fungus of the Mucorales order of the Zygomycetes class. Mucormycosis are rarely pathogenic in healthy adults, but can cause fatal infections in patients with immunosuppression and diabetes mellitus. Seventy-one years old male patient was diagnosed asthma in other center and was treated with oral and intravenous methyl prednisolone without learning diabetic history; applied to our clinic with the complaint of headache and facial pain, diplopia, loss of eye vision, and ptosis. On neurological examination, he presented a mild periorbital edema, left eye ptosis, blindness, total ophthalmoplegia and peripheral facial palsy. Laboratory findings show leucocytosis and hyperglycemia. Magnetic resonance imaging demonstrates progression of infection. On third day, a palatal ulcer was observed on the hard palate. Clinical suspicion of mucormycosis was confirmed by histological staining and culturing of tissue specimens from the palate. Based on these findings, a broad intravenous antibiotic and antimycotic therapy was initiated within 12 h after admission. Surgical debridement was applied twice to clean the cavity. Despite aggressive management, the patient died after 40 days from admission to our clinic. This case was reported to emphasize the mucormycosis which results in high mortality.v

Keywords: Mucormycosis, latent diabetes, immunosuppression, peripheral facial palsy, ophthalmoplegia

Application: 25.03.2011 **Accepted:** 17.08.2011

Introduction

Mucormycosis is a rare, occasionally fatal, opportunistic fungal infection that usually affects individuals debilitated by conditions such as uncontrolled diabetes mellitus (DM), hematologic malignancies, burns, malnutrition, uremia, cirrhosis, HIV infection, and immunosuppressive therapy. The most common pathogens are *Absidia*, *Rhizopus*, *Rhizomucor*, and *Mucor*. Rhinocerebral disease is characterized by low-grade fever, headache, malaise, sinus pain, bloody nasal discharge, periorbital and perinasal edema, ptosis of the eyelid, extraarticular muscle paresis, and progressive lethargy. Over time, disease extension from the nasal and paranasal sinuses may lead to palatal swelling, ulceration, necrosis, and even perforation of the hard palate. On clinical examination, large painless circumscribed necrotic greenish ulcers in the palate were obvious. Exposure of underlying bone may be seen. Orbital and intracranial invasion are additional complications of sinonasal presentations¹. Cerebral computed tomography (CCT) and magnetic resonance imaging (MRI) are useful modalities to assess the extent of the disease. The diagnosis of mucormycosis can be made by direct microscopy or histopathological examination, or by culture on Sabouraud dextrose agar. The detection of aseptate hyphae with right angled branching is pathognomonic. Amphotericin B (Amp-B) is partially effective therefore surgical debridement becomes essential². Herein, we report a case of mucormycosis localized in the bilateral maxillary, ethmoid sinuses, nasal cavity and cavernous sinuses in latent diabetes and asthma was treated with oral and intravenous methyl prednisolone. The patient was tried to be treated with endoscopic sinus surgery and administration of Amp-B.

Case Report

A 71 years-old male was diagnosed as asthma in other center was treated with oral and intravenous methyl prednisolone 80 mg per day without learning diabetic history. At the end of the treatment; he was admitted to the hospital because of symptoms of consisting of subfebril fever, headache and facial pain, diplopia, loss of eye vision, and ptosis at his left eyelid. Neurological ex-

amination revealed complete bilateral ophthalmoplegia, facial numbness on the left and incomplete peripheral facial palsy manifested.

A paranasal CT showed the presence of the soft tissue density obliterating bilateral maxillary, frontal sinuses and nasal cavity (Figure 1). Lumbar puncture was normal. The condition was diagnosed as pansinusitis and treated with administration of ceftriaxone 2 gr and metranidazol 1.5 gr per day. Routine blood tests showed hemoglobin of 16.0 g/dl, white blood cell 22.200, erythrocyte sedimentation rate was 100/h and the blood sugar was 294 mg/dl, urinary glucose (+++) and HbA1c: %7.4 (N: %4.5-6.5). VDRL and HIV were negative. The signs and symptoms worsened progressively despite aggressive treatment. At the third day, an ulcer on the hard palate with necrotic margins was observed on physical examination. The following days, the patient had complete blindness in the right eye and his left-sided periorbital pain and facial numbness worsened. Nasal examination showed presence of mucopurulent discharge.

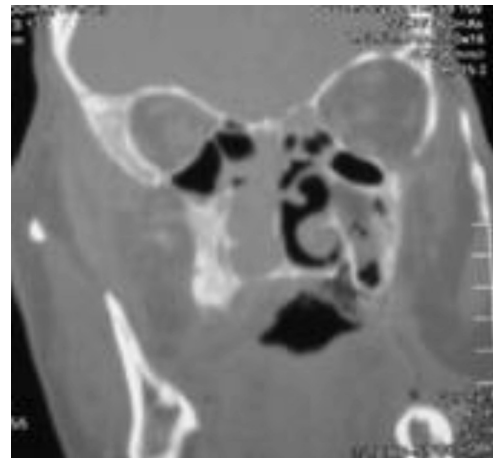


Figure 1: There is opacification of the right maxillary sinus with expansion of the sinus contents through the medial wall of the sinus into the nose on CT.

MRI fat-saturated post gadolinium T1 coronal in orbital image showed an inflammatory lesion involving the cribriform plate, ethmoid cells, sphenoid sinus and progression in invasion of the cavernous sinuses. Orbital involvement, maxillary bone erosion were seen which may raise the suspicion of invasive fungal infection (Figure 2).

Diagnosis was established by a biopsy of the palatal ulcer and nasal/sinus mucosa; histopathology revealed features compatible with mucormycosis. On histopathology examination, extensive areas of necrosis, hyalinized areas with the foci of fungal hyphae, micro abscess formation and granulomatous. The fungus was broad and rarely septate hyphae. The diagnosis of rhinocerebral mucormycosis (RM) was made on the basis of appearance of hyphae.

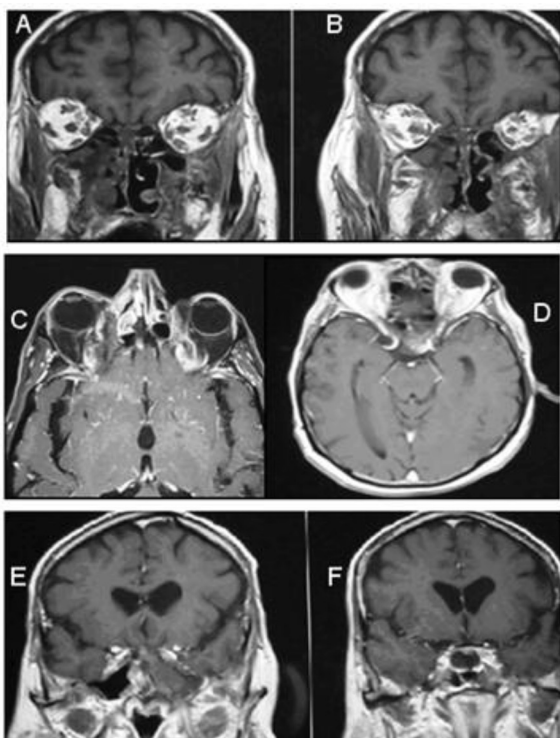


Figure 2:

Following diagnosis, intravenous Amp-B (5 mg/kg/day) was started immediately and the treatment consisted of surgical debridement of the affected tissues. The patient's renal and liver functions were monitored periodically and blood glucose was controlled. During the follow up period the condition of the patient worsened. Although our patient underwent early antimycotic treatment as well as surgical debridement of necrotic tissue, the progressive state of the infection with intracranial involvement at the time of admission resulted in the patient's death. Permission for autopsy could not be ob-

tained.

Discussion

RM is a rare, but potentially aggressive and fatal fungal infection. It is characterized by sinusitis and a painless, necrotic, black palatal or nasal septum eschar. It should be considered in all patients with chronic sinusitis, especially in immunocompromised patients³. The elevated white blood cell count and facial-orbital cellulitis suggested a bacterial etiology and CT scan showed right sinus opacification without evidence of bony erosion, which indicated either bacterial or fungal sinusitis.⁴ RM was suspected only when necrotic tissue appeared over the patient's hard palate. This diagnosis was later confirmed by histology. The patient had latent diabetes or poorly controlled DM before administration of prednisone. His resulting elevated glucose levels (>290 mg/dL) after corticosteroid therapy may have contributed to the spread of the fungal infection because fungi receive nourishment from sugars². In our case, there was latent diabetic or uncontrolled DM and prolonged systemic corticosteroid therapy for the treatment of asthma was the predisposing factor.

Clinically, they frequently present as fever, sinusitis, headache, periorbital or facial swelling, ptosis, visual loss and ophthalmoplegia. Cranial nerve palsies, proptosis and epistaxis have also been reported⁵. In our case, the symptoms were one week history of left sided facial numbness and pain, and physical examination revealed a mild periorbital edema, left eye ptosis, total ophthalmoplegia and peripheral facial palsy.

The diagnosis is based on a clinical picture revealing the invasive course of the disease and is confirmed by biopsy, where the specimen will show broad and rarely septate hyphae⁶. In our case, the diagnosis of RM was made on the basis of appearance hyalinized areas with the foci of fungal hyphae with right angled branching, if the diagnosis of mucormycosis was established by means of biopsy, culture, control CT scans or MRI are useful modalities to assess the extent of the disease². In our patient a pattern of anatomic involvement affecting

the nasal cavity, maxillary sinus, orbit, and ethmoid cells was observed. Additionally, fat-saturated T1 post gadolinium coronal MRI images show enhancement of the left sphenoid sinus and cavernous sinus, corresponding to mucormycosis invasion. The aggressive clinical features of the disease can suggest the diagnosis of the fungal infection, but the final diagnosis depend on the anatomopathological demonstration of fungal tissue invasion. Successful treatment of mucormycosis consists of aggressive surgical debridement of necrotic lesional tissue, systemic antifungal therapy and control of any underlying disease process (1). The patient was given 400 mg of Amp-B lipid complex every 24 hours. Unfortunately, Amp-B has a number of serious side effects, and renal toxicity is an almost invariable complication of therapy. He was prepared for surgery. A resection of the partial septectomy and hemipalatectomy were performed. Amp-B was used to flush the debrided areas.

In our case, RM was suspected only when necrotic tissue appeared over the patient's hard palate. The diagnosis was later confirmed by histology. The case of RM described in this report demonstrates the disease's rapidly progressive nature. Based on the patient's previous HbA1c levels, the patient had uncontrolled or unknown DM before administration of methylprednisolone for asthma. His resulting elevated glucose levels after corticosteroid therapy may have contributed to the spread of the fungal infection due to fungi receive nourishment from sugars.

Mucormycosis is a rapidly progressive disease that may have a fulminate course with fatal outcome unless diagnosed and treated rapidly¹. Despite aggressive treatment, the prognosis in poorly or uncontrolled diabetics with rhinocerebral disease is generally poor.

References

1. Tugsel Z, Sezer B, Akalin T. Facial swelling and palatal ulceration in a diabetic patient. *Oral Surg Oral Med Oral Pathol Oral Radiol Endod* 2004; 98(6): 630-36.
2. Bhansali A, Bhadada S, Sharma A, Suresh V, Gupta A, Singh P, Chakarbarti A, Dash RJ. Presentation and outcome of rhino-orbital-cerebral mucormycosis in patients with diabetes. *Postgrad Med J* 2004; 80(949): 670-74.
3. Hadzri MH, Azarisman SM, Fauzi AR, Kahairi A. Invasive rhinocerebral mucormycosis with orbital extension in poorly-controlled diabetes mellitus. *Singapore Med J* 2009; 50(3):107-109.
4. Ferguson AD. Rhinocerebral mucormycosis acquired after a short course of prednisone therapy. *J Am Osteopath Assoc* 2007; 107:491-93.
5. Harril WC, Stewart MG, Lee AG, Cernoch P. Chronic rhinocerebral mucormycosis. *Laryngoscope* 1996; 106:1292-97.
6. Park SK, Jung H, Kang MS. Localized bilateral paranasal mucormycosis: a case in an immunocompetent patient. *Acta Oto-*