

Unusual Presentation of a Uterine Rupture in an Unscarred Uterus: a Case Report and Review of the Literature.

Nebdesiz Uterüsda Olağandışı Rüptür Gelişimi: Vaka Sunumu ve Literatür İncelemesi

Önder Sakin¹, Bülent Kars¹, Orhan Ünal², Esra Yaşar¹, Zeynep Aybala Akıl¹, Orhan Balçık¹

¹ Dr. Lütfi Kırdar Kartal Eğitim ve Araştırma Hastanesi İstanbul

² Sakarya Üniversitesi Tıp Fakültesi

Abstract

- Objective** Rupture of the unscarred primigravid uterus is extremely rare and in primiparous patients it is thought to be negligible.
- Case** We aim to present the diagnosis and treatment of a rare case of spontaneous uterine rupture in a primigravid patient who declares that she had not undergone any obstetric interventions. But expressing that she has 2 pregnancy terminations in the postoperative questioning.
- Conclusion** We report this case to emphasize that uterine rupture can occur and should be included in the differential diagnosis of a primigravid woman presenting with pain and free fluid within the abdomen and to emphasize the importance of previous obstetric history.
(*Sakarya Med J* 2016, 6(3):156-160)
- Keywords** unscarred uterus, spontaneous uterine rupture, abdominal pain

Öz

- Amaç** *Primi gravid nedbesiz uteruslarda uterus rüptürü ile karşılaşmak nadir görülen bir durumdur. İlk gebeliği olan hastalarda bu klinik durum ile karşılaşmak kolaylıkla akla getirilmeyecek bir durumdur.*
- Olgu** *Bu vakada daha evvel herhangi bir obstetrik müdahale geçirmedigini beyan eden ancak postoperatif dönemdeki sorgulamada 2 tane gebelik terminasyonu geçirdiğini belirten primi gravid hastada karşılaştığımız spontan uterus rüptürü tanısı ve tedavisini sunmayı amaçladık.*
- Sonuç** *Bu olgu sunumu ile amacımız uterus rüptürü ileri gebelik haftalarında karın ağrısı ve batın içi sıvı koleksiyonu ile başvuran, nedbesiz primigravid hastalarda ayırıcı tanıda olmalıdır. Bu olgu sunumu ile özellikle obstetrik hikâyenin önemi vurgulanmak istenmiştir.*
(*Sakarya Tıp Dergisi* 2016, 6(3):156-160)

Anahtar Kelimeler: *Nebdesiz uterus, spontan uterus rüptürü, karın ağrısı.*

INTRODUCTION

Intrapartum uterine rupture is one of the most catastrophic events with a high maternal and fetal mortality and morbidity. Overall uterine rupture incidence in developed countries is lower than 1/1000¹. It is usually related with uterine scar mostly secondary to previous caesarean section. Rupture of the unscarred primigravid uterus is extremely rare and in primiparous patients it is thought to be negligible². The rate of uterine rupture for the unscarred uterus in series from the USA was 1/7648 to 1/16849^{1,3}. A 10-year Irish study by Gardeil et al showed that the overall rate of unscarred uterine rupture during pregnancy was 1 per 30,764 deliveries (0.0033%). No cases of uterine rupture occurred among 21,998 primigravidas, and only 2 (0.0051%) occurred among 39,529 multigravidas with no uterine scar⁴. javascript:showcontent('active','references');

Risk factors for intrapartum rupture of the unscarred uterus include grand multiparity, macrosomia, history of gestational trophoblastic disease and labor augmentation with misoprostol or oxytocin, instrumental deliveries, breech version and extraction, precipitous delivery, fundal pressure during second stage and prolonged labor^{1,2,5}.

We report a rare case of spontaneous uterine rupture in a primigravid patient who was supposed to have an unscarred uterus and no any risk factors. We report this case to emphasize that uterine rupture can occur and should be included in the differential diagnosis of a primigravid woman and to emphasize how important to take correct obstetric history is.

CASE

A 32 year old primigravid woman admitted to our labor floor at her 38th week of gestation with the complaint of acute onset abdominal pain, nausea, vomiting and uterine contractions. On physical examination blood pressure was 120/80mmHg, maternal pulse rate of was 84 beat/min. On vaginal examination there was no bleeding with the cervix 1 cm dilated and minimally effaced. The uterus was tender on palpation and there was abdominal rebound tenderness with minimal pressure. On ultrasonographic (USG) examination the fetal biometric measurements were appropriate with the last menstrual period of the mother. There was oligohidramnios

and interestingly maternal abdominal free fluid accumulation encountered on USG examination. The cardiotocography revealed a reassuring nonstress test with a baseline fetal heart rate of 150 beats /min. and tetanic uterine contractions were noted (figure 1). The laboratory analysis were within normal limits. The patient was questioned for previous gynecologic obstetric history and antenatal follow up of the current pregnancy. She told us that there was no previous gynecologic obstetric intervention and her antenatal period was uneventful.

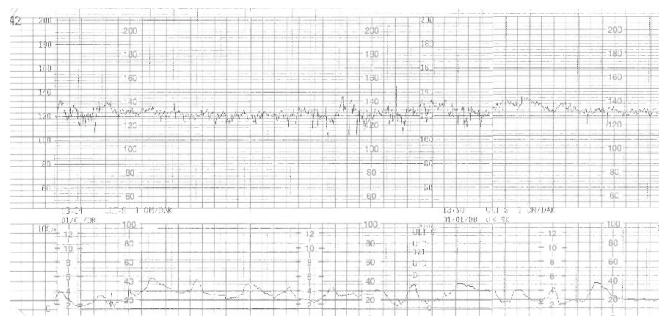


Figure 1: The NST report of the patient showing tetanic uterine contractions at admission

Since there was free fluid accumulation within the abdomen she was consulted to general surgery department to rule out any other possible conditions of acute abdomen. Physical examination did not exclude gastrointestinal tract perforation or injury. Immediate laparotomy was performed with general surgery team. The operation started with a midline vertical incision. There was 200 ml of free fluid with vernixcaseosa particles when the peritonium was opened. But there was no free blood or gastric content within the free fluid. On the operation field no sign of uterine rupture was encountered. So caesarean section with low transverse incision on the uterus was performed and 3315 gr live fetus delivered with an APGAR score of 9. The placenta and its components removed manually. When the uterus was palpated a 4x 4 cm non-bleeding rupture site was seen at the fundal part and the diagnosis of uterine rupture was ascertained (figure 2). Although the case was uterine rupture whole bowel and intestinal exploration performed to rule out coincidental gastrointestinal system perforation. The rupture site was closed with no 1 polyglactin 910 suture in a double layer fashion and operation was completed. Postoperative period was uneventful and the

patient was discharged on the 4.th postoperative day. After the operation the patient was questioned again for her past gynecologic obstetric history. She conceded two previous first trimester pregnancy terminations.

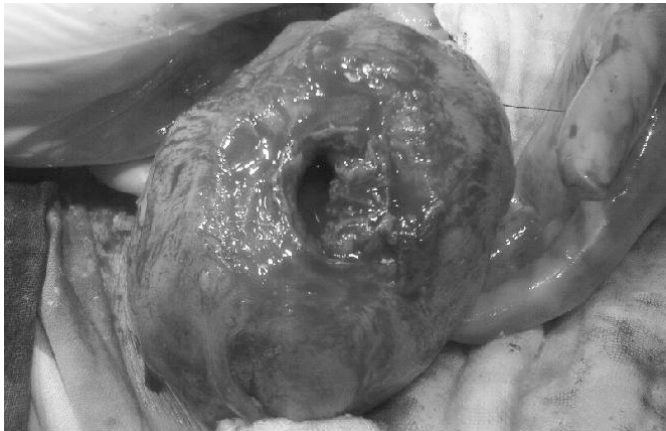


Figure 2: The view of uterine rupture (fundal site) at laparotomy

DISCUSSION

Uterine rupture is a rare but often catastrophic obstetric complication with an overall incidence of approximately 1 in 1514 pregnancies (0.07%)⁶. In modern industrialized countries, the uterine rupture rate during pregnancy for a woman with a normal, unscarred uterus is 1 in 7440 pregnancies (0.013%)⁶. This rate of spontaneous uterine rupture has not changed appreciably over the last 40 years, and most of these events occur at term and during labor. An 8-fold increased incidence of uterine rupture of 0.11% (1 of 920) has been noted in developing countries. This increased incidence of uterine rupture has been attributed to a higher-than-average incidence of neglected and obstructed labor due to inadequate access to medical care.⁶

Schrinsky and Benson reported 22 cases of uterine rupture in gravidas with unscarred uteri. Nineteen (86%) ruptures occurred during labor, and 3 (14%) occurred before labor⁷. This percentage was markedly different from that of gravidas with a previous uterine scar, for whom the timing of uterine rupture between labor and the antepartum period was nearly evenly distributed. In our case rupture had occurred at the beginning of the labor.
`javascript:showcontent('active','references');`

The signs and symptoms of uterine rupture largely depend on the timing, site, and extent of the uterine defect. Uterine rupture at the site of a previous uterine scar is typically less violent and less dramatic than a spontaneous or traumatic rupture because the scar is relatively avascular⁴. There are no reliable signs of fore coming uterine rupture before labour. Rupture may produce local pain and tenderness associated with increased uterine irritability and in some cases a small amount of vaginal bleeding. As the rupture site increases more pain is produced. In our case the first presenting symptom was sudden onset upper abdominal pain and there was rebound abdominal tenderness on physical examination. There was no vaginal bleeding nor hematoma formation on ultrasound examination. But free fluid accumulation seen on ultrasonography strengthened the diagnosis of uterine or gastrointestinal perforation.

The most consistent early indicator of uterine rupture is the onset of a prolonged, persistent, and profound fetal bradycardia. Other signs and symptoms of uterine rupture, such as abdominal pain, abnormal progress in labor, and vaginal bleeding, are less consistent and less valuable than bradycardia in establishing the appropriate diagnosis⁶. In our case there was no sign of fetal distress which made diagnosis more difficult. The reason of unaffected fetal hemodynamic condition can be fundal rupture with a thick uterine wall and no active bleeding from the rupture site.

The etiology of uterine rupture in an unscarred primigavida remains speculative. Drug abuse like cocaine, collagen deficiencies, uterine anomalies remain as other possible causes of spontaneous uterine rupture in an unscarred uterus⁸. In our case there was no any of these underlying risk factors. A misdiagnosis of onset of labor is one possibility but the fundal rupture is not consistent with the uterine contractions. The possible cause of fundal rupture as it was seen in our case is an undiagnosed uterine perforation during a previous termination of pregnancy. After the operation our patient conceded that she had two previous first trimester pregnancy terminations.

CONCLUSION

In conclusion, spontaneous uterine rupture of a primigravida with no known risk factor is extremely rare event and we report this case to emphasize that uterine rupture can occur and should be included in the differential diagnosis of a primigravid woman presenting with pain and free fluid within the abdomen. Also, once the diagnosis of uterine rupture is considered, all available resources must quickly and effectively be mobilized to successfully institute timely surgical treatment that results in favorable outcomes for both the newborn and mother. This case also shows us how important to take the correct obstetric history is.

References

1. Sweeten KM, Graves WK, Athanassiou A. Spontaneous rupture of the unscarred uterus. *Am J Obstet Gynecol.* 1995;172(6):1851-5; discussion 1855-6.
2. Kaczmarek JC, Kates R, Rau F, Kohorn E, Curry S. Intrapartum uterine rupture in a primiparous patient previously treated for invasive mole. *Obstet Gynecol.* 1994;83(5):842-4.
3. Miller DA, Goodwin TM, Gherman RB, Paul RH. Intrapartum rupture of the unscarred uterus. *Obstet Gynecol.* 1997;89(5 Pt 1):671-3.
4. Gardeil F, Daly S, Turner MJ. Uterine rupture in pregnancy reviewed. *Eur J Obstet Gynecol Reprod Biol.* 1994;56(2):107-10.
5. Pan HS, Huang LW, Hwang JL, Lee CY, Tsai YL, Cheng WC. Uterine rupture in an unscarred uterus after application of fundal pressure. A case report. *J Reprod Med.* 2002;47(12):1044-6.
6. E-medicine database [internet] Uterine Rupture in Pregnancy. Gerard G Nahum, Krystle Quynh Pham Jan 15 2008; available from <http://emedicine.medscape.com/article/275854-overview>
7. Schrimsky DC, Benson RC. Rupture of the pregnant uterus: a review. *Obstet Gynecol Surv.* 1978;33(4):217-32.
8. Gelbmann CM, Köllinger M, Gmeinwieser J, Leser HG, Holstege A, Schölmerich J. Spontaneous rupture of liver in a patient with Ehlers-Danlos disease type IV. *Dig Dis Sci.* 1997;42(8):1724-30.

