



A Rare Case Presenting with Symptoms of Familial Pheochromacytoma

Familiyal Feokromasitoma Semptomlarıyla Başvuran Nadir Bir Olgu

Mehtap Evran¹, Gamze Akkuş¹, Murat Sert¹, Tamer Tetiker¹

¹Cukurova University Medical Faculty, Department of Internal Medicine, Division of Endocrinology, ADANA

Cukurova Medical Journal 2015;40(3):593-596.

ABSTRACT

Pheochromocytoma is a rare tumor in which seen an incidence of 1 per 100.000 in the general population. Pheochromocytoma is a catecholamine producing neuroendocrine tumor arising from adrenal medulla. A 46-year-old man experienced headache, sweating and palpitation referred to our hospital. Familial pheochromocytoma was detected. We presented this case as whole family members had suffered from morbidities and deaths due to this disorder.

Key words: Pheochromocytoma, familial disorder, hypertension

ÖZET

Feokromasitoma 100.000 kişide bir görülebilen nadir tümörlerden birisidir. Genel olarak adrenal medulladan katekolamin salınımı ile karakterizedir. Kırk altı yaşında erkek hasta baş ağrısı, terleme, çarpıntı şikayeti ile kliniğimize başvurdu. Hastaya feokromasitoma tanısı konuldu. Bu yazıda ailesinde feokromasitomaya bağlı morbidite ve ölüm öyküsü olan bir hasta aktarılmıştır.

Anahtar kelimeler: Feokromasitoma, ailesel hastalık, hipertansiyon

INTRODUCTION

Pheochromocytoma is a rare tumor in patients with hypertension and general population that a catecholamine producing neuroendocrine tumor arising from adrenal medulla^{1,2,3}. Thus, these results in discharge of catecholamine, and is the second common cause of secondary endocrine hypertension, as adrenal dependent. Persistant-sustain hypertension, headache, and palpitations (especially sinus tachycardia) are the most common symptoms⁴.

Advances in diagnosis and genetics now challenge the traditional rule of 10 for pheochromocytoma (10% bilateral, 10% extra-adrenal, 10% familial, 10% malignant). Prevalence

of bilateral adrenal tumors is higher than 10 % in some familial phaeochromocytoma syndrome such as multiple endocrine neoplasia type 2 and Von Hippel- Lindau Syndrome². In this patient population misdiagnosed as primary hypertension is frequent. Consequently they will lose the chance of early diagnosis and curative treatment^{2,5}.

We aimed to present this rare case with familial pheochromocytoma, family members had suffered from morbidity and death.

CASE REPORT

A 46-year-old man experienced headache, sweating and palpitation referred to our hospital. His arterial tension was measured 200 mmHg as

systolic, 100 mmHg as diastolic from the right arm. 190 to 80 from the left lower extremity measurements were 210/110 from both sides. We saw that his has a diagnosis of pheochromocytoma from his previous reports. Reports showed the scintigraphic findings consistent with the accumulation of activity of neuroendocrine tumor in the right adrenal region. He underwent surgery, and applied right adrenalectomy in 1988. He has been without complaints until 2009. He admitted to hospital with same symptoms. He lost 10 kg in 6 months.

At that time glucagon challenge test was applied, and his urine epinephrine was 149 mcg/24 h (0-20 mcg/24 h), norepinephrine was 324 mcg/24h (18-80 mcg/24 h), dopamine 147 mcg/24 h(65-400 mcg/24 h), metanepine 21 mg (<1,3 mg/24 h), vanilmandelic acid (VMA) 7.6 mg/24 h (<6.8 mg/24 h), cortisol 132.5 mcg/dl, serum glucose 230 mg /dl. According to the test results he have received the diagnosis of type 2 diabetes mellitus.

His disease has been silent up to 2014 was admitted us with same symptoms. His urine

epinephrine was 2.4 mcg/24 h, norepinephrine was 604 mcg/24 h, normetanepine 1328mcg/24 h, metanepine 222 mg/24 h, VMA 7.6 mg/24 h, cortisol 322 mcg/dl. A multilobule, 4-4.8 cm in diameter, and heterogeneous mass was detected in the left adrenal gland by contrast-enhanced CT. This mass was closely adjacent to the renal vein, and was successfully resected. Preoperative doxazosin, and postoperative prednisolone treatments were given. We invited the family members due to suffering from the same symptoms. All of them had a diagnosis of pheochromocytoma. However, familial transmission was not taken into consideration, so far. His grandfather was dead from pheochromocytoma. His brother and two sisters were stricken pheochromocytoma from his stepmother. One of his stepsisters was died due to paraganglioma and pheochromocytoma. Our patient has four brother. All of them have a diagnosis of pheochromocytoma. One of them was operated. Family tree is shown in the figure 1.

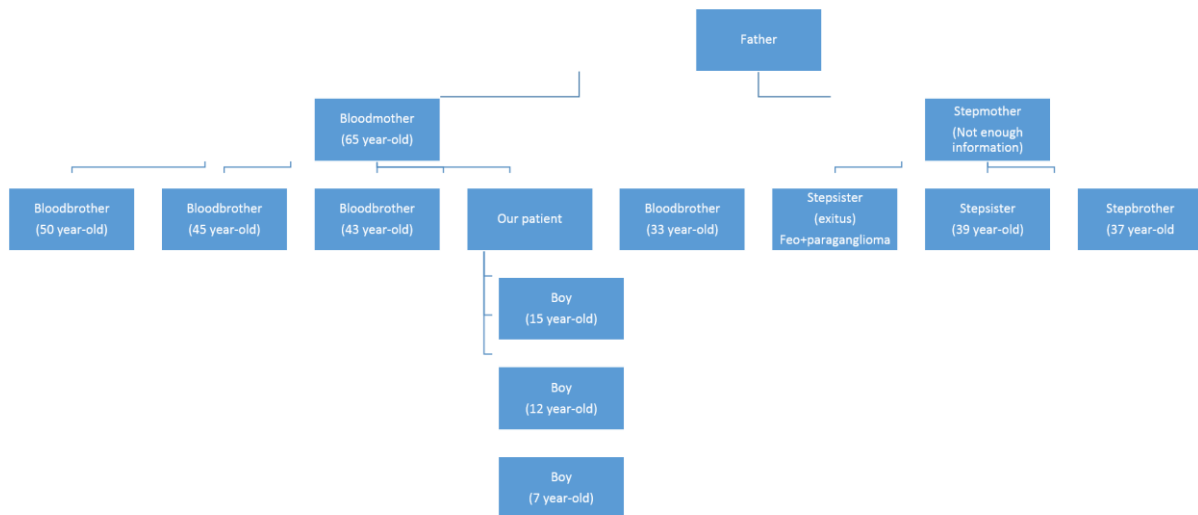


Figure1 The family tree for pheochromocytoma of patient.

DISCUSSION

Pheochromocytomas are rare neuroendocrine tumors with a highly variable clinical presentation. The serious and potentially lethal cardiovascular complications of these tumors are due to the potent effect of secreted catecholamines. The most common clinical presentations are headaches, sweating, palpitation and hypertension.

Hereditary pheochromocytomas occur in multiple endocrine neoplasia type 2 (MEN type 2), Von Hippel Lindau Syndrome, Neurofibromatosis type 1 and the familial paragangliomas^{6,7,8}. All patients with suspected pheochromocytoma should undergo biochemical testing. Standard biochemical tests include measurements of urinary and plasma catecholamines, urinary metanephrines (normetanephrine and metanephrine) and urinary VMA. Tumor localization should ideally only be initiated once there is unequivocal biochemical evidence for pheochromocytoma, CT scans or T2-weighted MRI for localization of pheochromocytoma^{9,10}. Genetic testing should be done in all patients with pheochromocytoma. Genetic testing is recommended to those patients who have a positive family history or those who are younger than 50 years, especially children. Germline mutations in five genes have been identified to be responsible for familial pheochromocytoma: The VHL gene, the Ret gene, the NF 1 gene and the genes encoding the B and D subunit of mitochondrial succinate dehydrogenase (SDHB and SDHD)¹¹.

In our case; all these symptoms were observed. Due to clinical findings and family history like pheochromocytoma, we wanted to study genetic diagnostic analysis. However, genetic analysis can not be performed because of technical difficulties.

CONCLUSION

Pheochromocytoma may relapse even in the late period as shown in our case. Therefore, physicians should be sceptical in resistant and complicated hypertension. Methods for genetic diagnosis are rising gold standard techniques to determine the potential risks, malignancy of disease, and for the maintenance of treatment.

Inform consent: We received the informed consent written from patients.

Conflict of interest: The authors declare that there is no conflict of interest that could be perceived as prejudicing the impartiality of the research reported.

Authors' contributions: All authors contributed to the manuscript. All authors read and approved the final manuscript.

REFERENCES

1. Santos P, Pimenta T, Taveira-Gomes A. Hereditary pheochromocytoma. *Int J Surg Pathol.* 2014;22:393-400
2. Kaltsas GA, Papadogias D, Grossman AB. The clinical presentation (symptoms and signs) of sporadic and familial chromaffin cell tumours (phaeochromocytomas and paragangliomas) *Front Horm Res.* 2004;31:61-75.
3. DeLellis R, Lloyd P, Heitz C. *Pathology and Genetics of Tumours of Endocrine Organs (IARC WHO Classification of Tumours)*, IARC Press, 2004 Lyon, France.
4. Martins R, Bugalho MJ. Paragangliomas/Pheochromocytomas: Clinically Oriented Genetic Testing. *Int J Endocrinol.* 2014; 2014: 794187. doi: 10.1155/2014/794187. Epub 2014 May 12.
5. Van Berkel A, Lenders JW, Timmers HJ. Diagnosis of endocrine disease: Biochemical diagnosis of pheochromocytoma and paraganglioma. *Eur J Endocrinol.* 2014;170:R109-119.

6. Neumann HP, Bausch B, McWhinney SR, et al. Germ-line mutations in nonsyndromic pheochromocytoma N Engl J Med. 2002;346:1459-66.
7. Plouin PF, Duclos JM, Soppelsa F, et al Factors associated with perioperative morbidity and mortality in patients with pheochromocytoma: analysis of 165 operations at a single center J Clin Endocrinol Metab. 2001;86:1480-6.
8. Maher ER, Eng. C. The pressure rises: update on the genetics of phaeochromocytoma Hum Mol Genet. 2002;11:2347-54.
9. Ilias I, Pacak K. Current approaches and recommended algorithm for the diagnostic localization of pheochromocytoma J Clin Endocrinol Metab. 2004;89:479-91.
10. Sahdev A, Sohaib A, Monson JP, et al CT and MR imaging of unusual locations of extra-adrenal paragangliomas (pheochromocytomas) Eur Radiol. 2005;15:85-92.
11. Bateurs C, Vantyghem MC, Leteurtre E, et al. Hereditary phaeochromocytomas and paragangliomas: a study of five susceptibility genes J Med Genet. 2003;40:e75.

Yazışma Adresi / Address for Correspondence:

Dr. Mehtap Evran,
Cukurova University Medical Faculty
Department of Internal Medicine, Division of Endocrinology
ADANA
E-mail:mehtap.evran@hotmail.com

Geliş tarihi/Received on : 22.01.2015.

Kabul tarihi/Accepted on: 02.03.2015