





LETTER TO THE EDITOR

Melanosis coli

Melanozis koli

İdris Kurt¹, Ebru Erol Uzunoğlu²

¹Kastamonu Training and Research Hospital, Gastroenterology Department, ²Pathology Department, Kastamonu, Turkey

To the Editor,

Melanosis coli (MC) refers to a pigmentation disorder characterized by the presence of black or brownish discoloration in the mucous membrane of the colon. This discoloration occurs due to the buildup of lipofuscin pigment among macrophages located in the lamina propria. The diagnosis of MC is often made by the visual examination of the intestinal mucosa during the procedure of colonoscopy. Nevertheless, in order to exclude other diagnosis apart from melanosis coli, it is necessary to do a microscopic investigation¹. The correlation between melanosis coli and neoplasia of the colonic epithelium has been a topic of considerable attention; nonetheless, it still lacks definitive clarification². The presence of colon darkening in melanosis coli may lead to potential confusion with colonic ischemia. This situation might provide a predicament for the gastroenterologist or surgeon³. In this study, we report a case of melanosis coli in a patient and provide a concise overview of the existing literature on the subject.

A 67-year-old female patient without any documented medical conditions visited our facility to undergo colonoscopy screening. The patient's medical history revealed a prior polypectomy treatment and a long-standing history of persistent constipation spanning almost three decades. The individual had been using anthraquinone laxatives that included sennosides over an extended period of time. After conducting laboratory analyses and seeing deviations in electrolyte and hormone levels, it was determined that metabolic circumstances were not responsible for the occurrence of constipation. The

patient refused undergoing any surgical procedures on her abdominal region or spinal column. On colonoscopy, the mucosa was diffusely filled with dark brown pigmentation in a snake-skin-like pattern, which was more remarkable in the right colon (Figure 1). The mucosa of the ileum exhibited no abnormalities. The observed characteristics were indicative of melanosis coli. Biopsies were obtained from diminutive polyp located in the cecum, as well as randomly selected samples from the ascending colon. The examination of the tissue samples indicated the presence of lipofuscin pigment inside the macrophages located in the lamina propria (Figure 2). In accordance with the aforementioned results, the patient received a diagnosis of melanosis coli, ceased the intake of laxatives, and began a dietary regimen high in fiber to address constipation.

The underlying pathology of the described appearance is the effect of anthraquinone laxatives. Laxatives that include anthraquinone have been shown to impede the absorption, motility, and secretion of colonocytes, leading to cellular demise. Macrophages phagocytose damaged colonocytes, resulting in intracellular digestion and subsequent accumulation of lipofuscin in the cytoplasm. The prevalence of this condition is higher in the right colon, with older individuals exhibiting a larger susceptibility⁴.

There are two fundamental aspects pertaining to melanosis coli that, in our perspective, experts should always bear in mind. One of the primary considerations is the endoscopic and extraluminal (occurring during laparoscopy or laparotomy) presentation of the colon, which may lead to

Address for Correspondence: İdris Kurt, Gastroenterology Department, Kastamonu Training and Research Hospital, Kastamonu, Turkey E-mail: idrisk8607055022@gmail.com
Received: 31.07.2023 Accepted: 08.09.2023

potential misinterpretation as ischemic colitis^{5,6}. Therefore, in order to address this issue, it is essential to get numerous endoscopic biopsies and conduct a comprehensive examination of the patient.

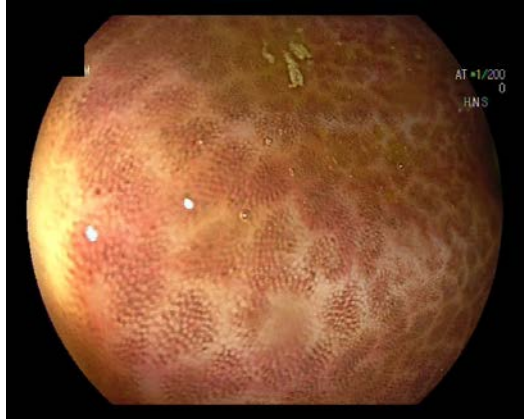


Figure 1. Endoscopic appearance of ascending colonic mucosa. Distributed dark brown pigmentation in a pattern resembling snakeskin.

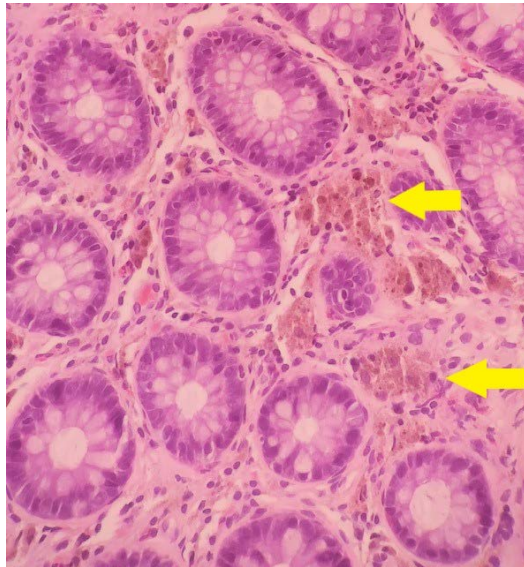

Figure 2. Accumulation of lipofuscin pigment in macrophages of the lamina propria (Hematoxylin-eosin stain, x20).

In the course of their study, Chaudhary et al. observed that an on-site pathology evaluation and awareness of melanosis coli might facilitate the formulation of a differential diagnosis. Furthermore, it should be noted that the small intestines remain mostly unaltered in terms of identification⁶.

The second aspect pertains to the potential danger of developing cancer. The validity of this idea continues to be a subject of debate and disagreement among the academic community. The disease is mostly regarded as benign, with no associated risk of cancer⁷. Nevertheless, several case reports and case series have shown the coexistence of melanosis coli with colorectal cancer. Biernacka-Wawrzonek et al. (2017) conducted a study with a total of 436 patients who had undergone surgery for colon cancer. Among the individuals included in the study, 11.9% were diagnosed with melanosis coli. Similar to the individual in question, the individuals diagnosed with melanosis coli were characterized by advanced age and female gender. The researchers reached the conclusion that the prevalence of melanosis coli has an upward trend as individuals age, similar to the pattern seen in colon cancer. However, the precise causal link between these two phenomena remains uncertain⁸. The present study included a systematic review and meta-analysis including randomized controlled trials and observational studies. The findings indicated a potential association between the use of anthraquinone laxatives and the development of colorectal cancer (OR:1.41; 95% CL:0.94-2.11). However, it is important to note that this association did not reach statistical significance. The researchers reached the conclusion that there is insufficient evidence to establish a causal relationship between the use of AQ laxatives and the development of colorectal cancer (CRC). Nevertheless, the observed tendency towards an elevated risk of CRC suggests the need for more inquiry using rigorous and well-designed trials⁹.

In conclusion, in the light of current knowledge, we accept melanosis coli as a benign condition unless proven otherwise by large randomized controlled studies. This harmless condition should be known especially by surgeons and all clinicians in order to avoid misdiagnosis and treatment, especially in other emergencies involving the abdomen. In addition, its treatment is simply the removal of the causative agent.

Author Contributions: Concept/Design : IK, EEU; Data acquisition: IK, EEU; Data analysis and interpretation: IK, EEU; Drafting manuscript: IK, EEU; Critical revision of manuscript: IK, EEU; Final approval and accountability: IK, EEU; Technical or material support: IK, EEU; Supervision: IK, EEU; Securing funding (if available): n/a.

Ethical Approval: Ethics Committee approval is not required as it is a case report. Informed consent is received from the case.

Peer-review: Editorial review.

Conflict of Interest: Authors declared no conflict of interest.

Financial Disclosure: Authors declared no financial support

REFERENCES

1. Abu Baker F, Mari A, Feldman D, Suki M, Gal O, Kopelman Y. Melanosis coli: a helpful contrast effect or a harmful pigmentation?. *Clin Med Insights Gastroenterol.* 2018;11:1179552218817321.
2. Liu ZH, Foo DCC, Law WL, Chan FSY, Fan JKM, Peng JS. Melanosis coli: Harmless pigmentation? A case-control retrospective study of 657 cases. *PLoS One.* 2017;12:e0186668.
3. Moeller J, Solomon R, Kiffin C, Ditchek JJ, Davare DL. Melanosis coli: a case of mistaken identity-a case report. *Perm J.* 2019;23:18-063.
4. Anoop KV. Melanosis coli: a case report. *Egypt J Intern Med.* 2021;33:23.
5. Ricciuti B, Leone MC, Metro G. Melanosis coli or ischaemic colitis? That is the question. *BMJ Case Rep.* 2015;2015:bcr2015212404.
6. Chaudhary BN, Sharma H, Nadeem M, Niayesh MH. Ischemic colitis or melanosis coli: a case report. *World J Emerg Surg.* 2007;2:25.
7. Gökçe AH, Gökçe FS. Prognosis in patients with melanosis coli: a prospective study. *Istanbul Medical Journal.* 2019;20:198–201.
8. Biernacka-Wawrzonek D, Stepka M, Tomaszewska A, Ehrmann-Jósko A, Chojnowska N, Zemlak M et al. Melanosis coli in patients with colon cancer. *Prz Gastroenterol.* 2017;12:22-7.
9. Lombardi N, Crescioli G, Maggini V, Bellezza R, Landi I, Bettioli A et al. Anthraquinone laxatives use and colorectal cancer: A systematic review and meta-analysis of observational studies. *Phytother Res.* 2022;36:1093-102.