
A NEW SURGICAL APPROACH, AN ALTERNATIVE TO PERCUTANEOUS BALLOON MITRAL VALVOTOMY IN PURE MITRAL STENOSIS: TEE GUIDED CLOSED MITRAL COMMISSUROTOMY WITH LIMITED ACCESS

E.AKINCI, MD
M.DEĞERTEKİN, MD
M. GÜLER, MD
B.DAĞLAR, MD
M. TUZCU, MD
C. YAKUT, MD

From: Koşuyolu Heart
and Research Hospital,
Koşuyolu, İstanbul

Transesophageal echocardiography guided closed mitral commissurotomy has been reexplored recently as a feasible alternative to percutaneous balloon mitral valvotomy in pure mitral stenosis. The feasibility and potential contributions of intraoperative TEE in closed mitral commissurotomy was investigated in this cilinical study.

Twentythree patients, 17 women, 6 men with a mean age of 38 ± 7.4 years was examined. Fifteen of them were normal sinus rhythm and rest of them in atrial fibrillation. Preoperative mean mitral valve area was 1.22 ± 0.20 cm² and, maximal mitral valve gradients was mean 17.1 ± 4.13 mmHg. Multiplane TEE was guided throughout the operation. A left anterior minithoracotomy with a port access for the Tubbs dilator was performed. In all of the cases a modified dilator was used. The measurement of the mitral valve area both before and after Tubbs applications and the degree of mitral insufficiency was quantitated. TEE also provided information about the mitral valve anatomy during the dilatation procedure.

Commissurotomy was succesfully performed in all patients. Postoperative MVA was 2.14 ± 0.32 cm², maximal mitral gradient was 5.7 ± 1.69 mmHg respectively. In eleven patients minimal mitral regurgitation was observed. Patients were discharged from the surgical intensive care unit on the postoperative 12th hour,

**Adress for
reprints:**

Koşuyolu Heart and
Research Hospital,
Koşuyolu
81020 İSTANBUL,
TÜRKİYE

and from the hospital postoperative day 3.6 ± 0.8 th.

TEE guided closed mitral commissurotomy is a simple, feasible and cost effective procedure. Definite evaluation of the mitral valve is demonstrated and, offers additional safety to the patients. Potential complications are also diagnosed earlier and more accurately. The minithoracotomy incision used during this procedure is in line with the current concept of minimal invasive surgery. The technique may be an alternative to percutaneous balloon mitral valvotomy for providing the efficacy and low cost.

Key Words: Surgical closed mitral commissurotomy, Tubbs dilator, transesophageal echocardiography

Closed mitral commissurotomy (CMC) was the first effective intervention in valvular heart disease. The possibility of opening a stenotic mitral valve by digital splitting of the fused commissures was apparently suggested by Samways as early as 1898 [1]. In 1923, Cutler inserted a valvulotome through the left ventricle, to cut both cusps [2]. The first successful finger splitting closed mitral commissurotomy was done by Souttar in 1925 [3]. Until the 1950s, many interventions on the stenotic mitral valve were reported [4-7]. The transventricular Tubbs dilator was designed to achieve dilatation for stenotic mitral valves during 1950s[8]. The dilator became popular

and was used for years. With the introduction of cardiopulmonary bypass, the technique of CMC for mitral stenosis was virtually abandoned in industrialized countries [9]. Balloon mitral valvotomy or surgical open mitral commissurotomy (OMC) substituted for CMC in selected cases [10,11].

Recently, minimal invasive procedures has become popular in cardiac surgery, It provides avoidance of the adverse effects of cardiopulmonary bypass (CPB) and, decrease in surgical complications due to large dissections [12]. We believe, CMC via left anterior minithoracotomy is a true non invasive procedure, because it is the combination of avoiding of both CPB and median sternotomy.

MATERIAL and METHODS

This clinical study was approved by the ethics committee of we Koşuyolu Heart and Research Hospital. At the Koşuyolu Heart and Research Hospital, 163 selected patients underwent CMC operation since 1985. Among these patients 23 selected cases with pure mitral stenosis (MS) underwent TEE(Ving MED CFM 800, Probe 5 MHz multiplane transducer, Santa Barbara, CA) guided CMC operation between August 1996 and May 1997. Seventeen of the patients were female and 6 were male. Mean age of the patients was 38 ± 7.4 years. All of the patients were

Table I: Preoperative Echocardiographic Findings in 23 TEE Guided CMC Patients

Mean MVA(cm^2)	1.22 ± 0.20
Mean Mitral Gradient(mmHg)	17.1 ± 4.13
Mean LA diameter (cm)	4.2 ± 0.8
Mean PA systolic pressure (mmHg)	40 ± 12
SEC (n)	2
Subvalvular Pathology (n)	
mild	18
moderate	5
severe	none
Calcification (n)	
mild	5
moderate	none
severe	none

TEE: Transesophageal echocardiography, CMC: Closed mitral commissurotomy.

evaluated clinically and echocardiographically. Coronary angiography and cardiac catheterization were performed in patients aged 40 and over. None of the patients had coronary artery disease. Preoperative mean mitral valve area evaluated by echocardiographic examination was 1.22 ± 0.20 cm² and, the mean mitral gradient was 17.1 ± 4.13 mmHg respectively. In selected of all of the patients degree of the stenosis, leaflet mobility and probable calcification, and subvalvar anatomy was investigated. Left atrial spontaneous echocontrast (SEC) was present in 2 patients. Left atrial thrombus was not revealed in any patient.

Mean left atrium (LA) diameter and pulmonary artery (PA) systolic pressure were 4.2 ± 0.8 cm and 40 ± 12 mmHg, respectively (Table I). Seventeen of the patients were in NYHA functional class III(%73.9), 4 in class IV(%17.4) , 2 in class II (%8.7) (Table III). The electrocardiograms revealed normal sinus rhythm in 17 patients and atrial fibrillation in 6 patients.

Pathologic changes in morphology of subvalvular apparatus was mild in 18 patients, and moderate in 5. Minimal nodular calcification was present in 5 patients. All of the patients underwent surgical procedure in elective conditions. A left anterior limited thoracotomy (12-16 cm) incision in the 4th intercostal space was performed routinely (Figure 1).

After dissecting the pericardium, a simple purse-string suture of 3/0 Ti-crone for left atrial appendage, and a U purse-string suture of 2/0 Ti-crone supported by pledgets for left ventricular apex were placed. A trochar was introduced from the 6th intercostal space for a port acces. The modified Tubbs dilator developed by us for much less invasive incision was introduced via the port acces (Figure II).

At that time TEE probe was placed intraoperative echocardiographic values were measured (Table I).

Tubbs dilator was introduced through the left-ventricular apex and was positioned across

Table II: Postoperative Echocardiographic Findings in 23 TEE Guided CMC Patients

MVA (cm ²)	2.14 ± 0.32
Mitral gradient (mmHg)	5.7 ± 1.69

MVA: Mitral valve area

Table III: Preoperative and Postoperative Functional Status of The Patients According to NYHA

NYHA Class	Preoperative		Postoperative	
	n	%	n	%
I	-	-	16	69.5
II	2	8.7	5	21.7
III	17	73.9	2	8.7
IV	4	17.4	-	-

NYHA: New York Heart Association.

the mitral valve. Commissurotomy was accomplished with the classic surgical technique and repeated by opening the blades of Tubbs dilator till the adequate mitral valve

area was reached. Throughout this procedure, TEE was performed. Echocardiographic values also were measured following procedure (Figure 1, Table II).

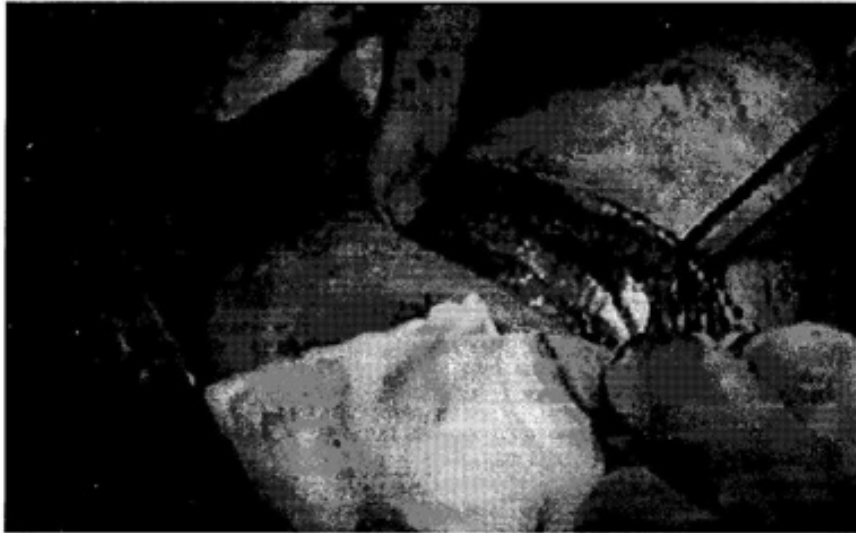

Figure 1: Left anterior mini thoracotomy performed with TEE guided CMC. Note that the incision is much more smaller than the classical anterolateral thoracotomy.



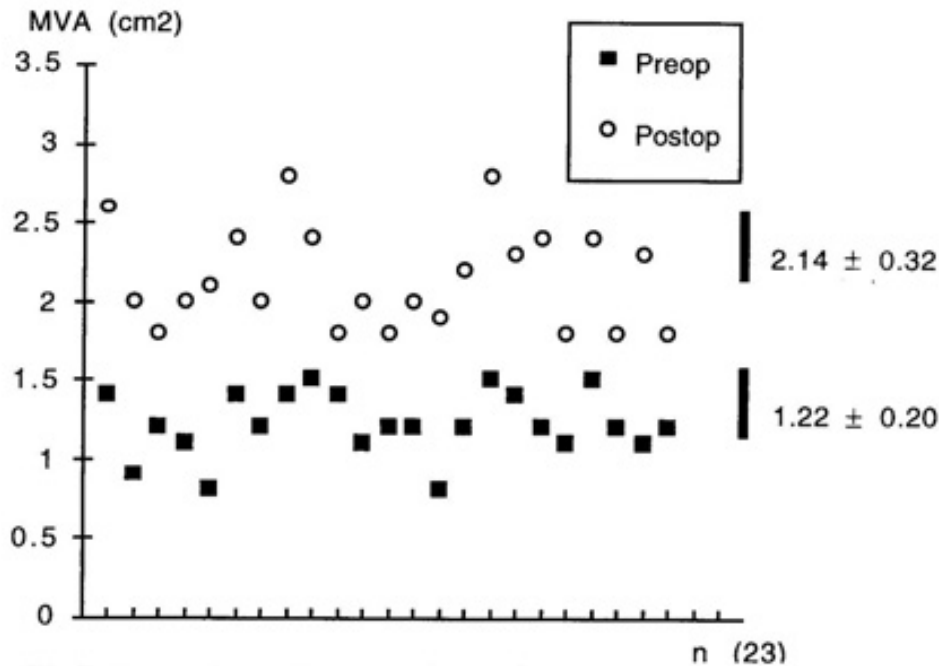
Figure II. The modified Tubbs dilator introduced via a port in 6th intercostal space.

RESULTS

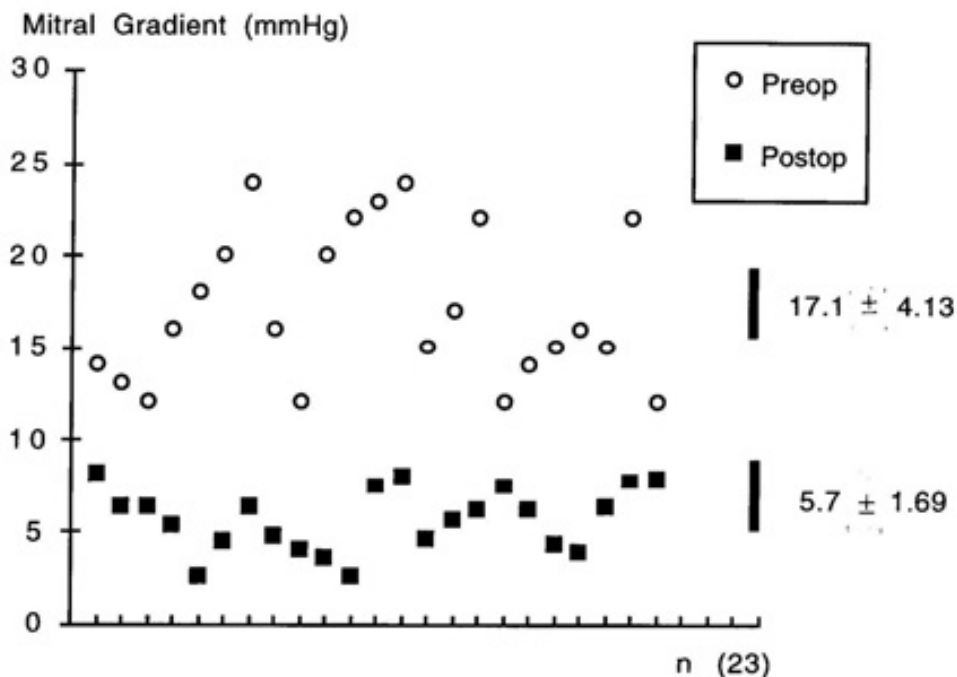
There was no mortality. Ventricular fibrillation occurred in 2 cases and they were defibrillated successfully during procedure. Adequate mitral valve area was achieved in all patients. There was no thromboembolic events. Any kind of surgical complication

such as bleeding, ventricular or atrial rupture, acute mitral insufficiency etc. was not encountered.

The postoperative mean MVA was measured 2.14 ± 0.32 cm² and the mean mitral gradient was 5.7 ± 1.69 mmHg respectively (Table II, Graphic I, II). Minimal mitral regurgitation (MR) occurred in 11 patients.



Graphic I. Comparison of preoperative and postoperative mitral valve areas of the TEE guided CMC patients.

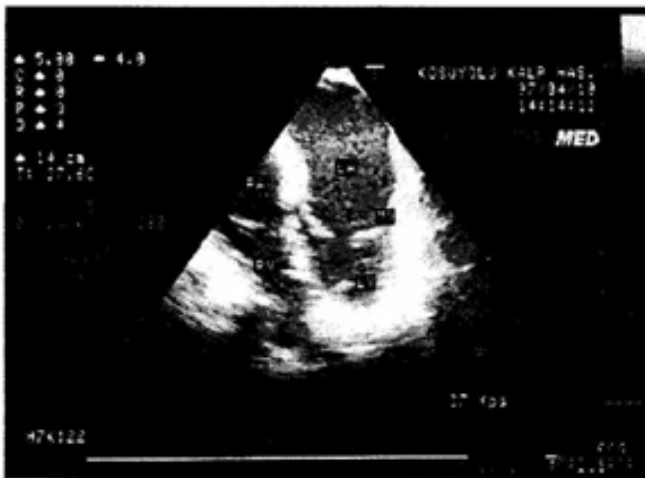

Graphic II. Comparison of preoperative and postoperative mitral gradients of the TEE guided CMC patients.

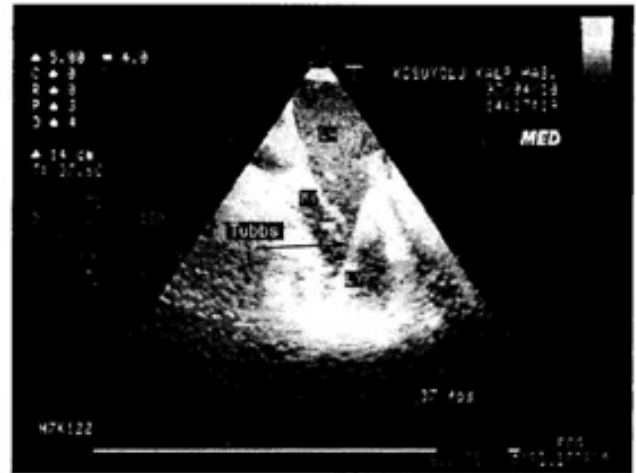The mean intensive care unit (ICU) surveillance was 12 ± 2.3 hours. Mean hospitalization period was 3.6 ± 0.8 days. 16 of the patients were in NYHA functional class I, 5 in class II and 2 in class III during post operative follow-up period (1 to 10 months) (Table III). The patients have been followed up between 13 days-to 9 months with a mean of 5.5 months. None of the patients have any complaints in this short follow up period. All of the patients have an active life style.

DISCUSSION

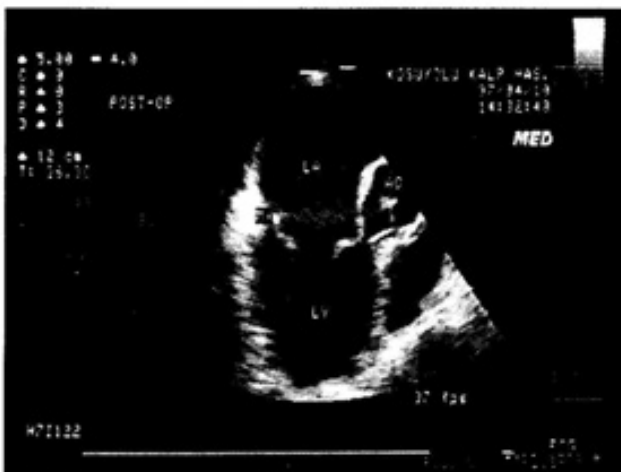Although open mitral commissurotomy and balloon mitral commissurotomy are preferred commonly in the treatment of mitral stenosis, we believe that TEE guided closed mitral commissurotomy via mini thoracotomy can be used as an alternative minimally invasive intervention in these cases. Closed mitral commissurotomy has been shown to result in comparable hemodynamic improvement to



A



B



C

Figure III.

Transverse four-chamber transesophageal views.

A: Severe stenosis of the mitral valve before commissurotomy.

B: Tubbs dilator (arrows) has passed between leaflets and is visible in the left atrium (LA).

C: Following commissurotomy the mitral stenosis is relieved, and there is no obstruction at the subvalvular apparatus.

balloon mitral commissurotomy on medium-term follow-up [13-15].

It has been stated that open mitral commissurotomy (OMC) does not have superiority to CMC in accordance to cardiac performance, thrombo-embolic event, functional status, reoperation risk and long-term results [16].

Although OMC provides the best condition for intervention to mitral valve, cardiopulmonary bypass and sternotomy are necessary in traditional OMC.

Recently, minimal invasive procedures become popular in cardiac surgery. It provides avoidance of the adverse effects of CPB and, decrease in surgical complications due to large dissections. Patients also experience more comfortable in the post operative period [12,17,18].

Although the advanced techniques in cardiopulmonary bypass, patients with severe pulmonary hypertension, diffuse coronary artery disease, or patients who have a pulmonary-renal neoplastic disease are of suitable candidates for heart surgery.

Occasionally in other circumstances such as during pregnancy CPB can be harmful for both the mother and the child. BMV, the other alternative procedure for mitral stenosis, provide similar hemodynamic and clinical improvements [13].

BMV has many complications such as cardiac perforation (0-4%), left to-right shunt at the atrial level due to dilatation of atrial septal puncture (35%). Rarely the defect is large enough to cause right heart failure [19-21].

Systemic arterial hypotension may occur due to transient occlusion of left ventricular inflow during balloon inflation [22]. In addition all patients are exposed to radiation during the procedure.

One of the major criticism of CMV is that the assessment of postoperative mitral insufficiency is by finger palpation, which has its own limitations and usually underestimates the regurgitation. The advent of TEE has made CMV no more a blind procedure; it can be compared more closely with an open mitral valvotomy or a balloon mitral valvotomy.

Intraoperative TEE guided CMC provides positioning Tubbs correctly, evaluating of

mitral valve motion and subvalvular apparatus before and following the procedure, measuring the mitral gradient and mitral valve area and revealing MR possibly occurring during procedure.

There were only two case-report studies on TEE guided CMC in literature, which one of them was a urgent case and the other elective (9,23,24). Criteria for patients selection is very important. A pliable mitral valve apparatus with mobile leaflets and minimal or no subvalvar disease, absence of calcification of leaflets or annulus, absence of mitral regurgitation, and absence of any associated significant cardiac lesion. In our institution the cost effect of TEE guided CMC is 1500 USD, of OMC is 4200 USD and of BMV is 3100 USD respectively.

TEE guided CMC by mini thoracotomy attempts not only to eliminate adverse effects of CPB but also to decrease incidence of pulmonary complications and wound infections. ICU surveillance of our patients was 12 ± 2.3 hours and hospitalization period was 3.6 ± 0.8 days.

Recently, less invasive cardiac surgery becomes popular. We believe and suggest that TEE guided CMC by mini thoracotomy is a less invasive method that would be performed in valve surgery, because CMC does not need CPB, and has cost-effective advantages over the other alternative methods.

Our aim is to develop TEE guided CMC technique and to perform this surgical procedure in the future with totally endoscopic conditions.

REFERENCE

- 1 - Samways DW: Cardiac peristalsis: Its nature and effects. *Lancet* 1898;1; 927
- 2- Cutler EC, Levine SA: Cardiomy and valvulotomy for mitral stenosis: Experimental observations and clinical notes concerning an operated case with recovery. *Boston Med J* 1923; 188;1023.
- 3- Souttar HJ: The surgical treatment of mitral stenosis. *Br Med J* 1925; 2; 603
- 4- Cutler EC, Beck CS: The present status of the surgical procedures in chronic

- valvular disease of the heart. Arch Surg 1929; 18;403
- 5- Bailey CP: The surgical treatment of mitral stenosis. (Mitral commissurotomy) Dis Chest 1949; 15; 377
 - 6- Harken DE, Ellis LB, Ware PF : The surgical treatment of mitral stenosis: I valvuloplasty. N Engl J Med 1948; 239; 801
 - 7- Baker C, Brock RC, Campbell M: Valvulotomy for mitral stenosis: Report of six successful cases. Br Med J 1950; 1;1283
 - 8- Logan A, Turner R: Surgical treatment of mitral stenosis with particular reference to the transventricular approach with a mechanical dilator. Lancet 1959; 2; 874
 - 9- Cohen GI, Casale PN, Lytle BW: Transesophageal echocardiographic guidance of closed mitral commissurotomy J. Am Soc Echocardiogr 1993; 6; 332-334
 - 10- Gross RI, Cunningham JN, Jr Snively SL : Long term results of open radical mitral commissurotomy: ten year follow-up study of 202 patients. Am J Cardiol 1981; 47; 821
 - 11- Farhat MB, Bonssadia H, Gandjbakhch I: Closed versus open mitral commissurotomy in pure noncalcific mitral stenosis: Hemodynamic studies before and after operation. J Thorac Cardiovasc Surg 1990; 99; 639
 - 12- Lytle BW: Minimally invasive cardiac surgery (Editorial). J Thorac Cardiovasc Surg 1996; 111;554-555
 - 13- Turi ZG, Reyes VP, Raju BS, et al: Percutaneous balloon versus surgical closed commissurotomy for mitral stenosis: A Prospective randomized trial. Circulation 1991; 83; 1179-1185
 - 14- Cohn LH, Alfred EW, Cohn LA: Long term results of open mitral valve reconstruction for mitral stenosis. Am J Cardiol 1985; 55; 731-734
 - 15- John S, Bashi VV, Jairaj PS : Closed mitral commssurotomy: Early results and long term follow-up of 3, 274 consecutive patients. Circulation 1983; 68; 891-896
 - 16- Hickey MSJ, Blackstone EH, Kirklin JW : Outcome probabilities and life history after surgical mitral commissurotomy: Implications for balloon commissurotomy. J Am Coll Cardiol 1991; 17; 29
 - 17- Subramanian VA, Sani G, Benetti FJ, Calafiore AM: Minimally invasive coronary bypass surgery: a multicenter report of preliminary clinical experience. Circulation 92 (Suppl) 1995; 1; 645
 - 18- ACuff TE, Landrean RJ, Griffith BP : Minimally invasive coronary arter bypass grafting. Ann Thorac Surg 1996; 61: 135-137
 - 19- Kirklin JW: Percutaneous balloon versus surgical closed commissurotomy for mitral stenosis. Circulation 1991;83: 1950-1
 - 20- L'Epine Y, Drobinsk G, Sotirov Y, et al: Right heart failure due to an inter-atrial shunt after percutaneous mitral balloon dilatation. Eur Heart J 1989; 10; 285
 - 21- Tuzcu EM, Block PC, and Palacios IF: Comparison of early versus late experience with percutaneous mitral balloon valvuloplasty. J Am Coll Cardiol 1991; 17; 1121
 - 22- Levine MJ Weinstein JS, Diver DJ : Progressive improvement in pulmonary vascular resistance after percutaneous mitral valvuloplasty. Circulation 1989; 79; 1061
 - 23- Reddy SC, Goel AK, Jain P, Sharma R, Wasir HS, Venugopal P: Transesophageal echocardiography during surgical closed mitral commissurotomy. Cardiology 1996; 87; 450-452
 - 24- Bedi HS, Sharma VK, Kohli V, Kasliwal RR, Trekan N: Closed Mitral Valvotomy: No more a Blind Procedure. Ann Thorac Surg 1994; 58; 608-609