

## DISORDERS OF SEXUAL DIFFERENTIATION AND SURGICAL CORRECTIONS

C. Özsoy, M.D.\* / A. Kadioğlu, M.D.\*\*\* / H. Ander, M.D.\*\*

\* *Professor, Department of Urology, Istanbul Medical Faculty, Istanbul, Turkey.*

\*\* *Associate Professor, Department of Urology, Istanbul Medical Faculty, Istanbul, Turkey.*

\*\*\* *Research Assistant, Department of Urology, Istanbul Medical Faculty, Istanbul, Turkey.*

### SUMMARY

Patients with ambiguous genitalia who applied to our clinic are investigated and they are classified as true hermaphroditism, male and female pseudohermaphroditism.

After chromosomal, psychological, hormonal, phenotypic and surgical evaluation, the final sex is determined and appropriate reconstructive surgery is performed.

In six of our 18 patients we reassigned the female sex to male. 2 of our 18 patients are true hermaphrodites (one being male and the other is female). 2 of them are female pseudohermaphrodites and 14 of them are male pseudohermaphrodites. 6 patients who underwent sexual reassignment were male pseudohermaphrodites.

In our opinion the most important aspect of sex reassignment is psycho - sexual character. Phenotypic, chromosomal or gonadal sex are of secondary importance in determining the final sex.

**Key words:** Intersex-reassignment of the sex-treatment

### INTRODUCTION

Historically the term ambiguity of the external genitalia was known in the old Persia, Babel and Mesopotamia. Afterwards the bisexual god Hermaphroditos appeared in the Greek-mitos, and this term is still being used for people with ambiguous external genitalia.

The first reports about ambiguous genitalia and its treatment were written by Turkish scientists Ibni Sina (Avicenna 930-1037) and Sharaf ed-Din (1465-

?). Developments in Cytogenetics and Radio-immuno assay after 1950's provided the easy diagnosis of sexual differentiation disorders.

**Normal sexual differentiation:** The normal human diploid cell contains 22 autosomal pairs of chromosomes and 2 sex chromosomes. Except spermatozoon and oocyt normal human cell is diploid. The chromosomal sex is determined at the time of fertilization. An XX female or male determined chromosomal sex, influences sexual differentiation by causing the bipotential gonad to develop either as a testis or as an ovary.

Until the 7th week of gestation the gonads are indistinguishable. In the presence of Y chromosome or H-Y antigen, which is located on the short arm of X chromosome, the medulla of gonads will begin testicular differentiation. In the presence of XX chromosomal pattern the gonads are destined to be an ovary. The appearance of Sertoli cells is the earliest recognizable event in testicular organogenesis. Leydig cells are apparent about at the 8th week of gestation.

In the absence of Y chromosome and H-Y antigen, if the zygote is XX after fertilization, the gonad differentiates as an ovary. A significant number of germ cells enter meiotic prophase to characterize the transition of oogonia into oocytes, which marks the onset of ovarian differentiation from the undifferentiated gonads.

The normal fetus is equipped with müllerian and wolffian ducts. The wolffian ducts have a potential of differentiating into the epididymis, vas deferens, seminal vesicles and ejaculatory ducts. The müllerian ducts form the uterine tubes, the uterus, and the upper

third of the vagina.

In the presence of a testis, the müllerian ducts involute under the influence of müllerian duct inhibitory factor, a nonsteroid macromolecule secreted by Sertoli cells. In the presence of an ovary or in the absence of a functional testis, müllerian duct differentiation occurs.

Differentiation of the external genitalia in males depends on the action of testosterone and particularly dihydrotestosterone, the 5 alpha reduced metabolite of testosterone (1). Dihydrotestosterone stimulates the growth of the genital tubercle, fusion of the urethral folds and descent of the labioscrotal swellings to form the penis and scrotum.

Impairment in the synthesis or secretion of fetal testosterone or its conversion into dihydrotestosterone, deficient or defective androgen receptor activity, or defective production and local action of müllerian duct inhibitory factor cause to incomplete masculinization of the male fetus (1).

There is an inherited tendency for the urogenital sinus to develop along female lines. The genital tubercle becomes the clitoris. The caudal part of the urogenital sinus forms the 2/3 lower part of the vagina. The urethral folds remain separate as the labia minora and the genital swellings form the labia majora.

The adrenal steroidogenesis defect in the female causes an increase in the adrenal originated androgens in congenital adrenal hyperplasia and virilization (2). Androgen deficiency in the male fetus and increased androgen levels in the female form ambiguous genitalia. Ambiguous genitalia also occurs due to anomalies, chromosomal or genital disorders.

Abnormal sex differentiation can be classified as follows:

#### **Gonadal differentiation disorders:**

Most of the gonadal differentiation disorders also known as chromosomal disorders, which cause ambiguity of external genitalia are the result of anomalies in sex chromosomes (3).

Meiotic nondisjunction of the zygote or misfolding of germinal cells during spermatogenesis or oogenesis cause gonadal disorders. Turner and Klinefelter syndromes are examples of gonadal differentiation disorders.

Apart from the classical type of Turner syndrome,

male types such as pure gonadal dysgenesis and mixed gonadal dysgenesis are also described (4,5,6). Klinefelter syndrome, also known as seminiferous tubule dysgenesis is one of the most common causes of infertility in males (7). The variants of this syndrome have at least two X chromosomes. Variants such as XXXY and XXYY are also described. Azoospermia, hypogonadism, small firm testes, gynecomastia are present.

#### **True Hermaphroditism:**

True hermaphrodites have both ovarian and testicular tissue present in either the same or opposite gonads. The ovotestis is the most common gonad found in true hermaphroditism. The external genitalia may simulate those of a male or female and inguinal hernia is usually present, and may contain a testis or an ovary.

The differentiation of the internal genitalia usually follows the pattern expected for the gonads present. In patients with an ovotestes the female aspects of the internal duct development are usually preserved. 60 % of true hermaphrodites have 46 XX karyotype. 46 XX+XY karyotype is also not infrequent. Hermaphroditismus vera may result from mosaicism, chimerism, Y to X chromosome translocation or an autosomal mutant gene.

#### **Male Pseudohermaphroditism:**

Male pseudohermaphrodites have gonads that are testes and have XY karyotype. The external genitalia are not completely masculinized. Male pseudohermaphroditism may result from testicular agenesis, testicular hypoplasia, failure in testosterone biosynthesis or failure of target tissue response to androgen (androgen receptor disorders).

#### **Complete Testicular Feminization:**

This type is characterized by female appearing external genitalia, a blind vaginal pouch, bilateral inguinal or abdominal testes, inguinal hernia and absent müllerian derivatives. The patients are raised as females. At the puberty some of the patients may exhibit mild virilisation and most of them have amenorrhea (8).

Androgen resistance in target organs or presence of abnormal receptors characterize this syndrome. The serum androgen levels are normal. Orchiectomy is indicated because of the increased risk of gonadal neoplasms. Thereafter estrogen replacement is necessary. Inheritance in all forms appears to be X linked.

**Incomplete Testicular Feminization:**

The masculinization of external genitalia is incomplete. The labio-scrotal fusion is not complete and wolffian duct derivatives are also partially present. Gilbert Dreyfus and Reifstein described patients with small phallus, hypospadias and pubertal gynecomastia (9). The psychological sex character and external genitalia influence the determination of male sex character.

**Perineoscrotal-pseudovaginal hypospadias:** is due to defective conversion of testosterone to dihydrotestosterone in the absence of 5 alpha-reductase. The external genitalia are not virilized. A blind vaginal pouch is present. The müllerian structures are present. Serum testosterone level is normal, but dihydrotestosterone level is low.

**Female Pseudohermaphroditism:**

These individuals have 46 XX karyotype and normal ovaries. The external genitalia are virilized (10). Enzymatic defect in the synthesis of cortisol, most common defect being 21 hydroxylase deficiency increases the production of androgen precursors. The degree of masculinization depends upon the stage of differentiation at the time of exposure to androgen. Prior to 12 weeks of gestation, high fetal androgen level leads to varying degree of labio-scrotal fusion and virilization of external genitalia. After 12 weeks of gestation androgens will produce only clitoral hypertrophy (10) (Fig.1).

It is inherited in autosomal recessive manner. In the male the phallus may be enlarged. These patients can sh

It is inherited in autosomal recessive manner. In the male the phallus may be enlarged. These patients can show cortisol and aldosterone deficiency. The treatment of female pseudohermaphrodites depends on the degree of virilization. In mildly virilized patients, steroid replacement and clitoridectomy is indicated and in heavily virilized patients vaginoplasty is indicated. The male pattern requires only glucocorticoid therapy.

**MATERIALS AND METHODS**

18 patients, with ambiguous genitalia, who applied to İstanbul Medical Faculty clinics, are discussed in this study. The patients are evaluated by age factor, genital examination, hormonal analysis, chromosomal analysis, psychosexual character, radiological and ultrasonographical examinations and by gonadal biopsy parameters. 2 of 18 patients are true hermaphrodites. 2 of them are female pseudohermaphrodites and 14 of them are male pseudohermaphrodites.

**Age:** 1 patient is under age 3, 4 patients are under age 10, 13 patients are under age 28.

**Hormonal Analysis:** Hormon levels of the two true hermaphrodites were normal. 2 female pseudohermaphrodites had low plasma cortisol level and incre-

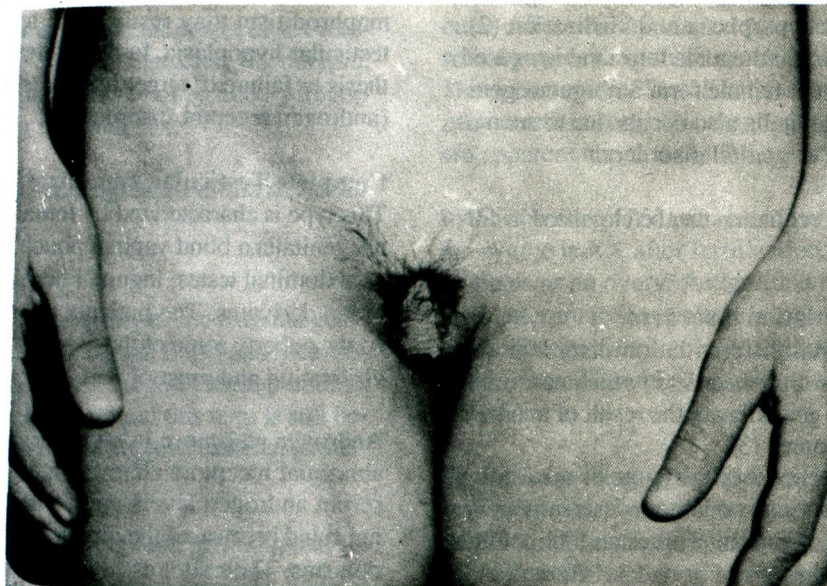

Fig. 1: Femal pseudohermaphrodite

ased 17-ketosteroid level in the urine.

5 of the male pseudohermaphrodites had low serum testosterone levels (patient no: 3,5,8,10,14), 4 of them had high serum testosterone levels (patient no:9,11,12,17) and the remaining had normal serum testosterone levels (patient no: 1,2,6,7,18).

Pregnyl (or LH-RH) test is performed to all of our patients and 8 of them had (+) response (patient no: 2,4,5,6,7,11,12,14).

**Genital Examination:** Except in one case (patient no:3) in all of the female pseudohermaphrodites we found cryptorchism and hypospadias on examination. Most of the male pseudohermaphrodites had a vaginal stump (blind ending vagina) (patient no: 2,3,5,9,11,14,17,18).

**Gonadal Biopsy:** All male pseudohermaphrodites underwent testicular biopsy (except patient no: 3, in whom the testes were absent). Light and electron microscopic examinations showed immature testis tissue, hyalinization, Leydig cell hyperplasia or Sertoli cell dominant pattern.

ter (Table I).

**Phenotype:** On the inspection of the external genitalia 14 cases have female and 4 cases have male phenotype (Table I).

**Psychological Sex:** 11 cases (patient no: 1,2,4,5,6,7,8,9,10,12,14) had male and 6 cases had female (patient no: 3,11,15,16,17,18) character.

## RESULTS

The parameters used in determining the real sex are various. Terms of gonadal, chromosomal, hormonal, psychological and phenotypic sex are widely used. We do not use most of the parameters which were used in determining the sex, anymore now. The classical female karyotype of 46 XX can be found in perfect males or in true hermaphrodites.

One of our cases (patient no:4) is true hermaphrodite, presenting in male phenotype and having 46 XX chromosomal pattern. In this case H-Y antigen is responsible for the presence of the testes. H-Y antigen is located on the short arm of X chromosome. This is why the chromosomal character is not enough for se-

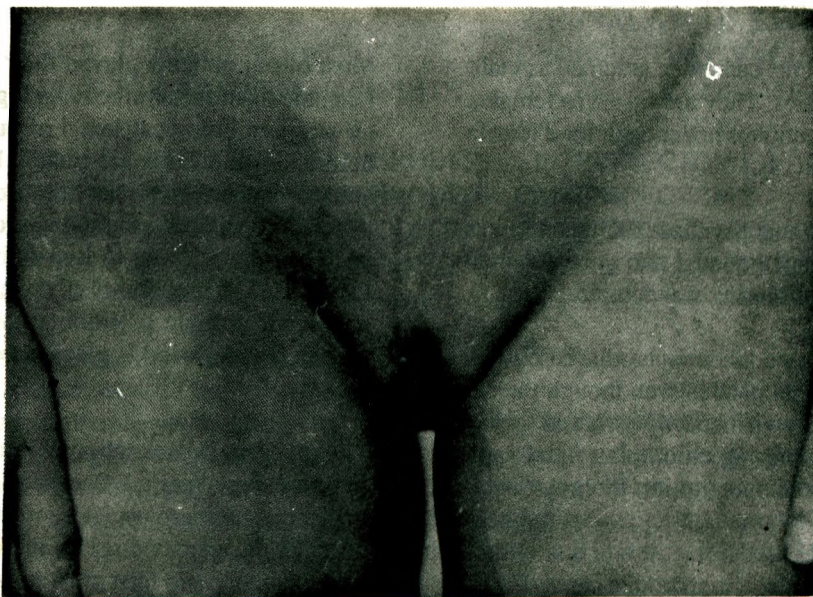


Fig. 2: Male Pseudohermaphrodite

**Chromosomal Analysis:** 14 male pseudohermaphrodites have 46 XY, 2 female pseudohermaphrodites have 46 XX, 1 true hermaphrodite has 46 XX-XY, 1 true hermaphrodite has 46 XX chromosomal charac-

tistical determination. The gonadal sex alone is also not enough for sexual determination. There are individuals whose psychological sex and the appearance of external genitalia is of female but they have testes as

**Table I: CHROMOSOMAL, PSYCHOSEXUAL, PHENOTYPIC CHARACTERS OF THE PATIENTS AND SEXUAL IDENTITY BEFORE AND AFTER TREATMENT**

PAT. NO.	AGE	KARYOTYPE	PSYCHOSEX.	PHENOTYP.	SEXUAL IDENTITY	
					(BEFORE)	(AFTER)
1	20	46 XY	MALE	MALE	MALE	MALE
2	6	46 XY	MALE	FEMALE	FEMALE*	MALE
3	18	46 XY	FEMALE	FEMALE	FEMALE	FEMALE
4	10	46 XX	MALE	MALE	MALE	MALE
5	5	46 XY	MALE	FEMALE	FEMALE*	MALE
6	28	46 XY	MALE	MALE	MALE	MALE
7	14	46 XY	MALE	FEMALE	MALE	MALE
8	11	46 XY	MALE	FEMALE	MALE	MALE
9	14	46 XY	MALE	FEMALE	FEMALE*	MALE
10	15	46 XY	MALE	FEMALE	FEMALE*	MALE
11	17	46 XY	FEMALE	FEMALE	FEMALE	FEMALE
12	17	46 XY	MALE	MALE	FEMALE*	MALE
13	8months	46 XX-XY	?	FEMALE	FEMALE	FEMALE
14	17	46 XY	MALE	FEMALE	FEMALE*	MALE
15	14	46 XX	FEMALE	FEMALE	FEMALE	FEMALE
16	9	46 XX	FEMALE	FEMALE	FEMALE	FEMALE
17	16	46 XY	FEMALE	FEMALE	FEMALE	FEMALE
18	18	46 XY	FEMALE	FEMALE	FEMALE	FEMALE

## \* CHANGE OF THE SEXUAL IDENTITY

gonads. These patients cannot be assigned as male because of their testes. They are raised as females and a surgical correction is not enough for a female gender (patient no: 18).

In most of our patients psychosexual gender was discordant with their gonadal and chromosomal sex and their sex of rearing was female.

In our two female pseudohermaphrodite cases with female psychological gender even though the external genitalia were virilized we assigned them a female sex by performing clitoroplasty and vaginoplasty and steroid substitution therapy (Table II).

In our 14 male pseudohermaphrodite cases (Fig. 2) phenotypes were mostly female but as a consequence of their male psychological gender we decided to assign them as male by excision of vaginal stump and orchiopexy+urethroplasty (Table I,II).

The chromosomal character is shown on the Table I and the diagnosis and operations are shown on the Table II.

Most of our patients played their gender role too long, the main factor in reassigning the sex character was psychological sex. 4 of our male pseudohermaphrodite cases are treated by orchiectomy and estrogen replacement because of their female psychological character and appropriate phenotype. They are allowed to live as infertile females (Table I). The probability of developing testicular neoplasm in male pseudohermaphrodites at the post pubertal period is eliminated in this type of therapy.

The other male pseudohermaphrodite cases were in post pubertal period. Because of personal, family and social pressures on our patients, we could not consider the increased risk of malignancy and allowed them to live in their male sexual identity. In some of our patients the sex assigned by their parents before application to the hospital is changed in opposite way by considering the patients' sexual psychology. All of our patients who are reassigned from female to male sex had been raised as female.

Etiology in our 14 male pseudohermaphrodite cases were: Gonadal agenesis or enzymatic defect in

**Table II: CLINICAL DIAGNOSE AND TREATMENT MODALITIES OF THE PATIENTS**

PATIENT		DIAGNOSE	TREATMENT
NO	AGE		
1	20	MALE PSEUDOHERMAPHRODITE	ORCHIOPEXY-URETHROPLASTY
2	6	MALE PSEUDOHERMAPHRODITE	ORCHIOPEXY-VAGINAL STUMP EXCISION-URETHROPLASTY
3	18	MALE PSEUDOHERMAPHRODITE	LAPAROTOMY-ESTROGEN
4	10	TRUE HERMAPHRODITE	OOPHERECTOMY-URETHROPLASTY
5	5	MALE PSEUDOHERMAPHRODITE	ORCHIECTOMY-URETHROPLASTY- VAGINAL STUMP EXCISION
6	28	MALE PSEUDOHERMAPHRODITE	ORCHIOPEXY-URETHROPLASTY
7	14	MALE PSEUDOHERMAPHRODITE	ORCHIOPEXY-URETHROPLASTY
8	11	MALE PSEUDOHERMAPHRODITE	ORCHIOPEXY-URETHROPLASTY
9	14	MALE PSEUDOHERMAPHRODITE	ORCHIOPEXY-URETHROPLASTY- VAGINAL STUMP EXCISION
10	15	MALE PSEUDOHERMAPHRODITE	ORCHIOPEXY-URETHROPLASTY- VAGINAL STUMP EXCISION
11	17	MALE PSEUDOHERMAPHRODITE	ORCHIECTOMY-VAGINOPLASTY
12	17	MALE PSEUDOHERMAPHRODITE	ORCHIOPEXY-URETHROPLASTY- VAGINAL STUMP EXCISION
13	8 months	TRUE HERMAPHRODITE	ORCHIECTOMY-VAGINOPLASTY
14	17	MALE PSEUDOHERMAPHRODITE	ORCHIOPEXY-URETHROPLASTY VAGINAL STUMP EXCISION
15	14	FEMALE PSEUDOHERMAPHRODITE	CLITERIDECTOMY-VAGINOPLASTY
16	9	FEMALE PSEUDOHERMAPHRODITE	CLITERIDECTOMY
17	16	MALE PSEUDOHERMAPHRODITE	ORCHIECTOMY-ESTROGEN
18	18	MALE PSEUDOHERMAPHRODITE	ORCHIECTOMY-ESTROGEN

the 4th or 5th stage of testosterone biosynthesis in the gonads e.g. 17-20 desmolase, 17 ketosteroid reductase. In these patients the answer to Pregnyl stimulation test were negative (patients no: 3,8,17,18). If serum testosterone level increases by Pregnyl stimulation but serum dihydrotestosterone level remains unchanged the 5 alpha reductase which plays the main role in differentiation of external genitalia, defect should be considered (patients no: 1,2,5,15).

Meanwhile in patients with remarkable answer to Pregnyl stimulation deficiency of placental gonadotrophins should be taken into account. We found cryptorchism in most of our cases and this proves our above mentioned concept.

#### DISCUSSION

The treatment of sexual differentiation disorders should be completed before the age of three. By this way the social and familial problems will be prevented. Unfortunately most of our cases were in the puberty and older age group. Insufficient education of the family and absence of health insurance may be the reason.

When they had the chance of applying to a medical center they were in complex psychological problems. Out of 18 patients six adopted their new sexual identity (patient no: 2,5,9,10,12,14) (Table I).

All of our patients who were reassigned from female to male sex were raised as females. After our surgical

intervention the female gender was changed to male one.

We want to emphasize that surgical reconstruction is done according to the individuals' chromosomal, gonadal and most importantly to their psychosexual character, and the sex of rearing is of paramount importance, chromosomal and gonadal sexes are considered to be of secondary importance.

#### REFERENCES

1. Wilson JD. Recent studies on the mechanism of action of testosterone. *N Eng. J Med.* 1972; 287: 1284-91.
2. Quazi QH, Thompson MW. Genital changes in congenital adrenal hyperplasia. *J Pediatr.* 1972; 80: 653.
3. Barr ML, Bertram EG. A morphological distinction between neurones of the male and female and the behaviour of the nucleolar satellite accelerated nucleoprotein synthesis. *Nature* 1949; 163: 670-77.
4. Davidoff F, Federman DD. Mixed gonadal dysgenesis. *Pediatrics* 1973; 52: 725-42.
5. Ford CE, Jones KW, Polani PE, et al. A sex chromosome anomaly in a case of gonadal dysgenesis (Turner's syndrome). *Lancet.* 1959; 1: 711-13.
6. Turner HH. A syndrome of infantilism, congenital webbed neck and cubitus valgus. *Endocrinology* 1938; 23: 566-74.
7. Klinefelter HF Jr, Reifenstein EC Jr, Albright I. Syndrome characterized by gynecomasty, aspermatogenesis without A-Leydigism and increased excretion of follicle stimulating hormone. *Clin Endocrinology* 1942; 2: 615-27.
8. Griffen JE, Wilson JD. The syndrome or androgen resistance. *N Eng J Med.* 1980; 302:198.
9. Dreyfus G et al. Etude d'un cas familial d'androgynoidisme avec hypospadias grave, gynecomastie et hyperestrogenie. *Ann Endocrinol. (Paris)* 1957; 18:93-101.
10. Prader A. Der Genitalbefund beim Pseudohermaphroditismus feminus des kongenitalen Syndromes. *Helvetica Paediatrica A la.* 1954; 9:231.