

AXILLOCEPHALIC ARTERIOVENOUS GRAFT : A NEW ALTERNATIVE FOR HEMODIALYSIS

**Atike Tekeli, M.D.* / Serdar Akgün, M.D.* / C. Selim İsbir, M.D.*
Ali Civelek, M.D.* / Koray Ak, M.D.* / Feyyaz Baltacıoğlu, M.D.****

* *Department of Cardiovascular Surgery, School of Medicine, Marmara University, Istanbul, Turkey.*

** *Department of Radiology, School of Medicine, Marmara University, Istanbul, Turkey.*

ABSTRACT

Different types of vascular accesses are used for patients who need hemodialysis due to chronic renal failure. The most commonly used are arteriovenous fistulae (AVF) which can be classified as autogenic or prosthetic grafts. Prosthetic arteriovenous grafts can be placed into anatomic or, in complicated case, into extra-anatomic locations. In this paper, we present a patient who had the AVF operation four times and the femoral arteriovenous graft operation twice and we report an alternative hemodialysis access, "axillocephalic graft interposition".

Key Words: Arteriovenous graft, Hemodialysis access, Chronic renal failure.

INTRODUCTION

In patients with chronic renal failure requiring hemodialysis catheterization, arteriovenous fistulae (AVF), and prosthetic arteriovenous (AV) shunt grafts are used for vascular access. Among these, the most commonly used are Cimino-Brischia radiocephalic fistulae. However,

previous vascular accesses, subclavian vein thrombosis or intrinsic arterial diseases precludes the use of this access (1,2).

In patients with terminal stage chronic renal failure and those with peripheral vascular disease, the vascular accesses might not be used for longer durations, thus creating a very important problem for the patients (3).

It is well known that autogenous AVF are better than prosthetic AV grafts. However in the patients with complications, prosthetic grafts are used very often because of the AVF dysfunction and thrombosis due to insufficient blood flow (4,5). Besides the usual anatomic positions, prosthetic grafts can also be used in the extra-anatomic locations. These can be created between the brachial artery-jugular vein, axillary artery-jugular vein, brachial artery-cephalic vein and axillary artery-contralateral axillary vein (3,6-9).

In diabetic patients with peripheral vascular disease, the upper extremity is a suitable location for both the autogenous fistulae and prosthetic grafts because atherosclerosis is not commonly seen in this anatomic location.

CASE REPORT

A 49-year-old male with end stage chronic renal failure who required hemodialysis was referred to our department from another hospital for vascular access. He previously had the AVF operation for four times and the femoral AV graft operation twice. In his past history, he has had hypertension for twenty years regulated with medication, type 2 diabetes mellitus for 25 years, acute myocardial infarction eighteen years ago and an aortobifemoral bypass surgery due to atherosclerotic stenosis of terminal aorta nine years ago.

As the vascular accesses previously created could not be used due to thrombosis, an AV graft in extra-anatomic location was planned. The patient was placed in supine position under general anesthesia, a 5 cm horizontal incision was made from the distal portion of the clavicle for axillary artery and cephalic vein exploration. After heparinization a 6 x 70 mm. GORETEX (Gore&Associates, Flugstaff, Arizona, USA) e-PTFE graft was implanted in a loop fashion between the axillary artery and the cephalic vein. The patient was anticoagulated with warfarin postoperatively. The patient had an uneventful recovery and an angiography on the 7th day postoperatively showed a patent graft (Fig. 1).

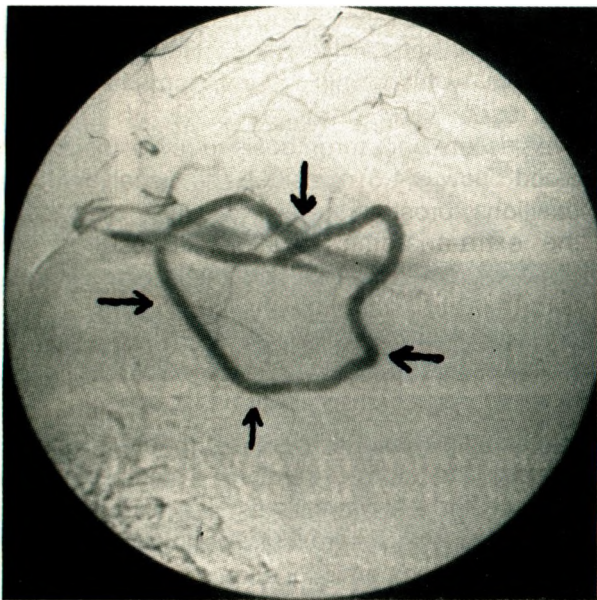


Fig. 1.: Axillocephalic arteriovenous graft: A new alternative for hemodialysis: Arrows show the ePTFE graft between axillary artery and cephalic vein.

DISCUSSION

Vascular access procedures are the lifeline of patients with end stage renal disease maintained on hemodialysis. The function of the access will greatly determine the quality of life that this patient population will enjoy.

In patients with end stage chronic renal failure associated with diabetes mellitus and peripheral vascular problems the patency of vascular accesses are negatively affected (3). In a study Fernstrom et al, showed that diabetes mellitus impairs the patency of AVF (10). Our patient previously had an aortofemoral bypass operation which enabled us to implant femoral AV graft which is the mostly used AV graft procedure in our clinic. Also all of his upper extremity (bilateral radial and brachial) AVF were thrombosed. We thought that the extra-anatomic AV graft implantation was a good alternative to the permanent subclavian catheter which was the last choice in this patient. The most common locations used for extra anatomic AV fistula are the upper extremity with a graft between the axillary artery and the brachial or antecubital vein, loop graft between axillary artery and vein. At first we planned a subclavian arteriovenous graft interposition which is a cross-sternal bridge AV fistula but the patient had a history of coronary artery disease and there was a possibility of median sternotomy for coronary artery bypass graft (CABG) operation. Thus an interposition done between subclavian artery and vein could cause a problem during median sternotomy. So we changed our plan, and decided to make a graft interposition between the axillary artery and the cephalic vein. In fact an interposition between the axillary vein and the axillary artery could be an alternative way but we saw that the cephalic vein was well developed thus we made an interposition between axillary artery and cephalic vein. In conclusion, we think that patients like our case who have no choice other than permanent catheter for hemodialysis access or who are unable to have CAPD, this extra-anatomic graft location might be a good alternative. Since grafts are foreign bodies, complications of these accesses are common. Reported one-year patency rates vary from 65% to 75% (11,12). Thrombosis is the most common complication, swelling and infection are the other important complications seen with these

accesses. The treatment of these complications is challenging and requires excellent judgement, creativity and technical proficiency. The efficacy and durability of these grafts needs to be determined by the short and long term follow-up of many similar cases.

REFERENCES

1. Wong V, Ward R, Taylor J, Selvakumar S, How TV, Bakran A. Factors associated with early failure of arteriovenous fistula for haemodialysis access: *Eur J Vasc Endovasc Surg* 1996;12:207-213.
2. Rubens F, Wellington JL. Brachiocephalic fistula: a useful alternative for vascular access in chronic hemodialysis. *Cardiovasc Surg* 1993;1:128-130.
3. Ono K, Muto Y, Yano K, Yukizane T. Anterior chest wall axillary artery to contralateral axillary vein graft for vascular access in hemodialysis: *Artif Organs* 1995;19:1233-1236.
4. Humphries AL Jr, Colborn GL, Wynn JJ. Elevated basilic vein arteriovenous fistula: *Am J Surg* 1999;177:489-491.
5. Nakagawa Y, Ota K, Sato Y, Fuchinoue S, Teraoka S, Agishi T. Complications in blood access for hemodialysis: *Artif Organs* 1994;18:283-288.
6. Polo JR, Sanabia J, Garcia-Sabrido JL, Luno J, Menarguez C, Echenaguisa A. Brachial-jugular polytetrafluoroethylene fistulas for hemodialysis: *Am J Kidney Dis* 1990;16:465-468.
7. McCann RL. Axillary grafts for difficult hemodialysis access. *J Vasc Surg* 1996;24:457-461.
8. Polo JR, Vazquez R, Polo J, Sanabia J, Rueda JA, Lopez-Baena JA. Brachiocephalic jump graft fistula: an alternative for dialysis use of elbow crease veins: *Am J Kidney Dis* 1999;33:904-909.
9. Hill SL, Seeger JM. The arm as an alternative site for vascular access for dialysis in patients with recurrent access failure: *South Med J* 1985;78:37-40.
10. Fernstrom A, Hylander B, Olofsson P, Swedenborg J. Long and short term patency of radiocephalic arteriovenous fistulas. *Acta Chir Scand* 1988;154:257-259.
11. Haimov M, Burrows L, Baez A, Neff M, Slifkin R. Alternatives for vascular access for hemodialysis: experience with autogenous saphenous vein auto grafts and bovine heterografts: *surgery* 1974;75:447.
12. Oakes D, Spees EK Jr, Light JA, Flye MW. A three year experience using modified bovine arterial heterografts for vascular access in patients requiring hemodialysis. *Ann Surg* 1978;187:423.