



## ORIGINAL RESEARCH

### RETROPERITONEAL CASTLEMAN'S DISEASE: REPORT OF FOUR CASES

Pinar Yazıcı<sup>1</sup>, Ünal Aydın<sup>1</sup>, Oktay Tekesin<sup>2</sup>, Murat Zeytinlu<sup>1</sup>, Murat Kılıç<sup>1</sup>, Mine Hekimgil<sup>3</sup>  
Ahmet Coker<sup>1</sup>

<sup>1</sup>Ege University, School of Medicine, Department of General Surgery, Izmir, Türkiye

<sup>2</sup>Ege University, School of Medicine, Gastroenterology Division, Izmir, Türkiye

<sup>3</sup>Ege University, School of Medicine, Department of Pathology,, Izmir, Türkiye

#### ABSTRACT

Castleman's Disease (CD) located in the retroperitoneum is a rare entity which has both benign and malignant potential. We presented our series of four patients with retroperitoneal neoplasm of the lymphatic chain and evaluated the management of these patients.

Over a five-year period, all patients who had intraabdominal lymphadenomegaly with an unknown etiology or were diagnosed with Castleman's Disease of the retroperitoneum were retrospectively reviewed. Data included demographic features, surgical management and outcomes.

Four patients with CD were detected, three males and one female with a mean age of 54 years. All patients had a unicentric mass located in the retroperitoneal area. Three cases complete excision of the mass and one with a mass associated to the pancreatic head underwent a pancreaticoduodenectomy. Three of the histological examinations were revealed to be of the hyaline vascular type and one was a mixed type microscopically. The recovery period was uneventful for all the patients. In the follow-up period, no recurrence was detected.

This unusual anomaly of the lymphatic chain, particularly in the retroperitoneal area, should be kept in mind in the differential diagnosis of retroperitoneal tumors. The histological examination can reveal a mixed type CD even in this location. For unicentric tumors, surgical excision is the effective curative management and our series proved the efficacy of this method.

**Keywords:** Intraabdominal lymphadenomegaly, Castleman's disease, Total excision

### RETROPERİTONEAL CASTLEMAN HASTALIĞI: DÖRT OLGU SUNUMU

#### ÖZET

Castleman Hastalığı hem malign hem de benign olma riski olan retroperitoneal yerleşimli olan nadir bir patolojidir. Biz bu çalışmada retroperitoneal lenfatik zincirde malignitesi olan dört hastayı ve tedavi yaklaşımlarını değerlendireceğiz.

Beş yılı aşkın bir süredir etiyojisi bilinmeyen karın içi lenfadenopatisi ya da Castleman hastalığı tanılı hastalar retrospektif olarak tarandı. Cerrahi tedavileri ve sonuçlar değerlendirildi.

Castleman hastalığı tanılı, yaş ortalaması 54 olan üç erkek bir kadın hasta bulundu. Tüm hastalarda retroperitoneal alanda yerleşimli izole bir kitle mevcuttu. Üç hastaya total eksizyon uygulanırken pankreas başı ile ilişkili bir kitleye pankreatikoduodenektomi uygulandı. Bir tane mikst tip haricinde tüm patolojik değerlendirmeler hiyalin vasküler tip olarak rapor edildi. Tüm hastaların iyileşme periyodu sorunsuz geçti ve takip periyodunda nüks saptanmadı.

Özellikle retroperitoneal alan yerleşimli lenfatik zincirdeki bu nadir anomali retroperitoneal tümörlerin ayırıcı tanısında mutlaka akılda bulundurulmalıdır. Bu bölge yerleşimli Castleman hastalığı mikst tip de olabilir. Tek odaklı tümörlerde etkin küratif tedavi için cerrahi eksizyon yeterlidir ve bu yazı sonuçları bunu desteklemektedir.

**Anahtar Kelimeler:** Karın içi lenfadenopatiler, Castleman Hastalığı, Total eksizyon

#### İletişim Bilgileri:

Pinar Yazıcı, M.D.

Ege University, School of Medicine, General Surgery, Izmir, Türkiye

e-mail: drpinaryazici@gmail.com

Marmara Medical Journal 2009;22(3);243-247



## INTRODUCTION

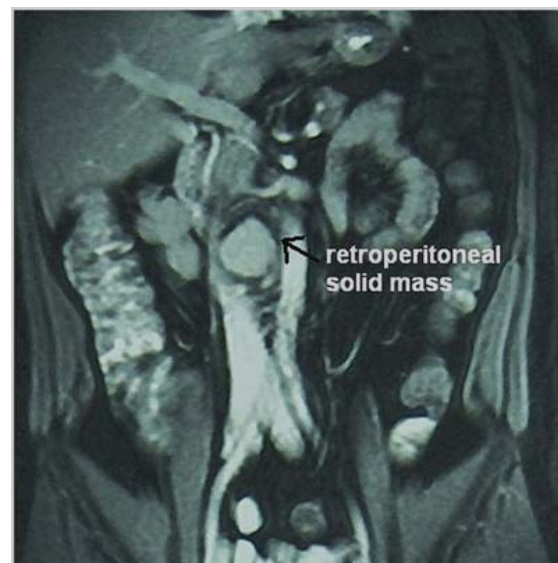Castleman's disease (CD), or angiofollicular lymph node hyperplasia, is a rare entity characterized by formation of benign lymph node masses, first described by Castleman et al. in 1956<sup>1</sup>. It is mostly recognized in the mediastinum, but it rarely manifests clinically within the retroperitoneum. CD in the retroperitoneum is especially unusual, accounting for only 7% of all reported cases (400 patients so far)<sup>2</sup>. The importance of localization is that there is a relatively high potential risk for the development of malignancy with the retroperitoneal tumors. CD can be histologically divided into two types: the plasma cell type, and the hyaline-vascular type which is more common, accounting for 90% of all cases<sup>3</sup>. Isolated case reports have described the plasma cell type and rare hyaline vascular type arising in the retroperitoneum<sup>4-6</sup>. To our knowledge, a mixed type of plasma cell and hyaline-vascular types occurring in the retroperitoneum has not been previously reported. In this series of four patients with retroperitoneal CD, we also presented a case of mixed type tumor arising in this location, which was diagnosed due to periodical abdominal pain.

## CASE REPORTS

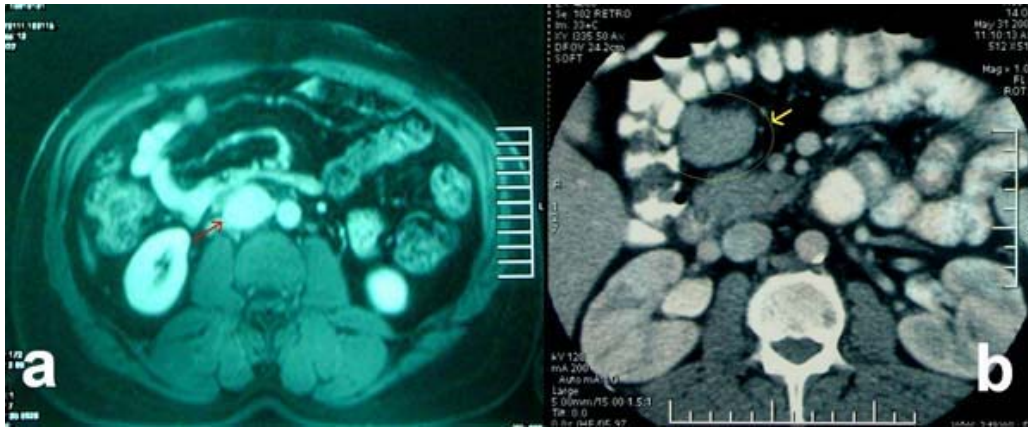
Between May 1999 and March 2006, four patients were detected with CD after a retrospective review of the case records. Demographic variables, clinical features, diagnostic methods, operative procedures were evaluated. Data also included the postoperative complications, hospital stay, pathological examination and follow-up period. The informed consent form was obtained from the patients in question.

Three male and one female with a mean age of 54 (46-62) were detected. Two patients were asymptomatic whereas other two had abdominal pain. Laboratory evaluation and hematological parameters were within normal ranges. C-reactive protein, one of the acute phase reactants, was also normal. All patients had routinely performed chest X-rays,

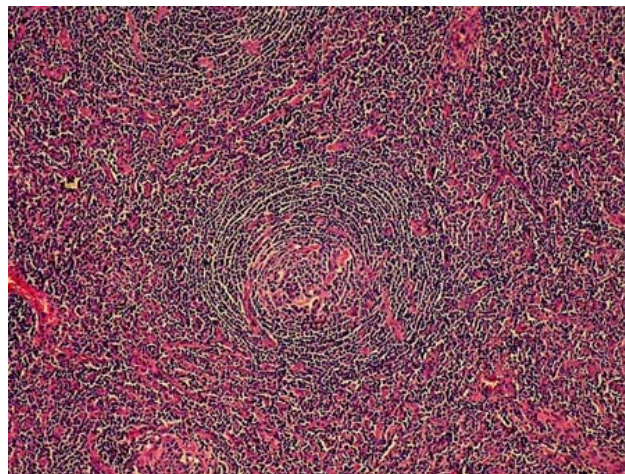
ultrasonography and computed tomography (CT) of the abdomen. All of the masses were found in unicentric localization and the most frequent localization of the masses was the retroperitoneal area (Figure 2a) and next to the pancreatic head, mostly at the posterior side. In case no 2, CT revealed a solid mass arising from the mesentery of the transverse colon and extending to the infero-posterior of the pancreatic head (Figure 2b). Mean diameter of the tumors was 4,1 cm ranging between 3cm and 5,5 cm. Three patients underwent only total excision of the mass, whereas one patient required pancreaticoduodenectomy. Pathological examinations revealed hyaline-vascular type lymphadenomegaly (Figure 3, case no. 3) in all patients except one patient (case no.2) whose histological findings demonstrated mixed cellular type including both hyaline-vascular and plasmacytic type cell features (Figures 4a-b). All patients had an uneventful recovery period. Mean hospital stay and follow-up was 6 days (range: 3-14 days) and 34.5 months (13-72 months), respectively. No recurrence was revealed by radiological studies in the follow-up period.



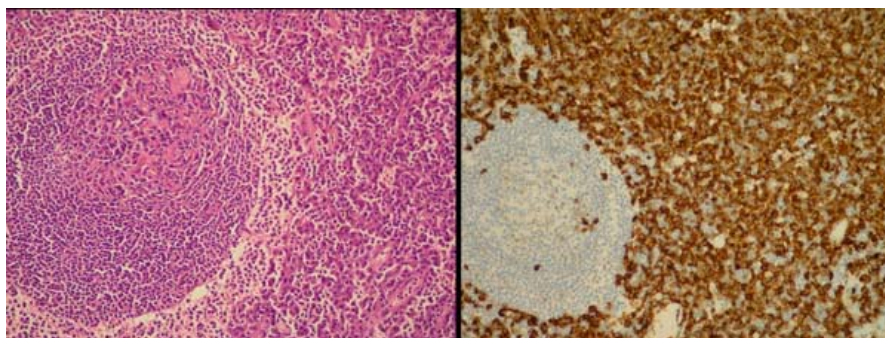
**Figure 1:** Isolated solid mass, 24x32mm in size, (lymphadenomegaly) located between vena cava inferior and aorta (case no 3).



**Figure 2:** a) solid mass (about 3 cm in diameter) located posterior to the vena cava inferior, b) right paraaortic mass arising from the mesentery of the transverse colon



**Figure 3:** Concentric layering of mantle zone cells around the hyalinized germinal centers in case no. 3



**Figure 4:** a) Glomerulization of germinal centers and plasma cell infiltration of the interfollicular area in case no. 2 (H&E, x20) b) Immunohistochemical staining of plasma cells with CD138 (DAB, x20).





**Table 1.** Demographic characteristics and treatment modalities of the patients

Patient number	Age	Gender	Clinical features	Diagnostic methods	Localization and diameter of LAM	Operative procedure	Pathological Examination	Hospital stay(days)	Follow-up (months)
P1-FY	62	F	Abdominal pain, weight loss	USG, CT	Pancreatic head 30*18mm	Pancreatico-duodenectomy	Hyaline-vascular	14	72
P2-NT	53	M	Abdominal pain, fatigue	USG, CT**	Arising from mesentery of the transverse colon, posterior of the pancreatic head, right paraaortic area, 55*31mm	Total excision of the mass	<b>Mixed type;</b> Hyaline-vascular type + plasma cell type	3	13
P3-GG	46	M	asymptomatic	USG, CT*, MRI	Posterior to the uncinat process, interaortocaval LAM, 24x37 mm	Total excision of the mass	Hyaline-vascular type	6	18
P4-RA	57	M	asymptomatic	USG, CT	Posterior to the inferior vena cava 32x45mm	Total excision of the mass	Hyaline-vascular type	4	36

P:patient , USG: ultrasonography, CT: computed tomography, MRI: magnetic resonance imaging, LAM: lymphadenomegaly

\* picture 1, \*\* picture 2b

## DISCUSSION

Tumors located in the retroperitoneum include various groups of neoplasms of benign or malignant origin. However, malignant potential is considerable for retroperitoneal masses. On the other hand, benign retroperitoneal tumors comprise only about 20% of all primary retroperitoneal neoplasms<sup>7</sup>. Because of deeper location on the lymphatic chain, clinical presentation of these patients with retroperitoneal CD constitutes a real problem for the physician to diagnose. As with the patients presented in our study, patients with the plasma cell type tumor of CD usually present some symptoms, whereas those with the other types are generally asymptomatic. In our series, only one patient had symptoms related to the abdomen and it was considered due to close relationship of the tumor with the pancreatic head, preoperatively. The hyaline vascular histological subtype is the most common, accounting for 90% of cases whereas the plasma cell type (10%) is less common and less vascular<sup>8</sup>. In addition, CD is mostly indistinguishable from other diseases despite preoperative radiographic work-ups and even after operative observation. These two

characteristics of this rare entity make it difficult to obtain the precise diagnosis prior to surgery. The usual appearance of this entity by CT is that of a nonspecific homogeneous mass and homogeneously hypoechoic feature on US. In our patients, US and CT imaging demonstrated almost typical characteristics, but no remarkable evidence of malignancy. Additionally, magnetic resonance imaging (MRI) is also one of the diagnostic techniques. Although MRI has some advantages like higher soft tissue contrast, the intensity characteristic is not specific for CD.

Once localized CD is removed, the prognosis is very good, but not for multicentric disease. Unicentric CD has generally no progression or association with other tumors and simple resection is curative in 90-95% of cases, whereas multicentric CD can progress to lymphoma (5%) and usually requires systemic therapy. Those patients generally follow an aggressive, often fatal clinical course associated with hepatosplenomegaly, multifocal lymphadenopathy, and abnormal liver/renal function, mostly caused by infectious complications or the development of malignancies<sup>3</sup>. In some cases, the surgeon cannot safely remove all the disease, but this



does not necessarily mean it will come back. Because partial removal may help the prognosis and the disease may not return, the tumoral mass should be extracted as much as possible. These recommendations are not conforming for both the patients with multicentric disease or associated HIV infection. In one study, 50% of the people with multicentric CD had died by the end of 2½ years. In our series, fortunately, none of them had multicentric masses. All but one underwent total excision without remnant tissue in the abdomen. One had to have advanced resectional procedure due to close relation with the pancreatic head and suspicious frozen section results. If the frozen section is feasible intraoperatively, it should be used to determine the operative strategy and the resection margins.

In conclusion, although retroperitoneal CD is a rare entity, it should be included in the differential diagnosis. We suggest that when CD is clinically suspected for retroperitoneal solid masses after meticulous preoperative evaluation, only total excision of the mass is curative with a good outcome.

## REFERENCES

1. Castleman B, Iverson L, Menendez VP. Localized mediastinal lymph node hyperplasia resembling thymoma. *Cancer* 1956; 9:822- 830
2. Rare diseases in numbers. [[http://ec.europa.eu/health/ph\\_threats/non\\_com/docs](http://ec.europa.eu/health/ph_threats/non_com/docs)] it is available from this website.
3. Ziv Y, Shikiar S, Segat M, Orda O. Bilateral localized Castleman disease of the retroperitoneum. *Eur J Surg Oncol* 1993; 19:188-191
4. Moon WK, Kim WS, Kim IO, Yeon KM, Han MC. Castleman disease in the child: CT and ultrasound findings. *Pediatr Radiol* 1994;24:182-184
5. Joseph N, Vogelzang RL, Hidveg D, Neiman HL. Computed tomography of retroperitoneal Castleman disease (plasma cell type) with sonographic and angiographic correlation. *J Comput Assist Tomogr* 1985;9:570-572
6. Singletary L. A, Karcnik T. J, Abujudeh H. Hyaline vascular-type Castleman disease: a rare cause of a hypervascular retroperitoneal mass. *Abdom Imaging* 2000; 25:207-209
7. Okada S, Maeta H, Maeba T, Goda F, Mori S. Castleman Disease of the Pararenal Retroperitoneum: Report of a Case. *Surg Today* 1999; 29:178-181
8. Keller AR, Hochholzer L, Castleman B. Hyaline vascular and plasma cell types of giant lymphnode hyperplasia of the mediastinum and other locations. *Cancer* 1972;29:670-683.