

PHOTO QUIZ

A young man with a 12 cm cyst of the spleen

Metin SENOL, Hakan ÖZDEMİR, Zehra ÜNAL ÖZDEMİR, İbrahim Tayfun ŞAHİNER

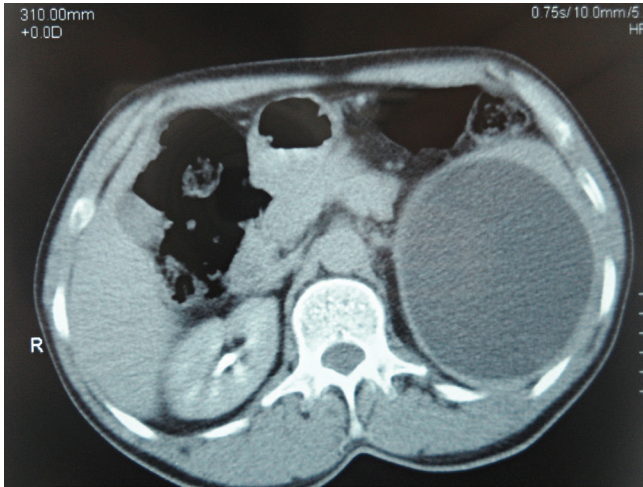


Figure 1: An abdominal CT scan reveals a 12 cm cystic mass originating from the spleen.

A 45-year-old man was admitted to the general surgery clinic with abdominal pain, especially on his left side. He also complained about abdominal distension for the last few months. Physical examination revealed both tenderness and a mass in the left upper quadrant of the abdomen. There were no other pathological findings. There were no chronic diseases or surgery in his medical history.

In laboratory examinations, complete blood count (CBC), biochemistry and urine tests were normal. There was no sign for hypersplenism. On radiological examination, the abdominal X-ray was normal but abdominal ultrasonography (USG) and computed tomography (CT) revealed a pure cystic mass in the spleen which was 12 cm in radius with a thick wall structure that was pushing the spleen superiorly and left kidney inferiorly (Figure 1).

An operation was planned for the patient, who was diagnosed as having a splenic cyst. Pneumococcus vaccination administered to the patient preoperatively. During the exploration through a median incision, it was observed that in addition to the splenomegaly, the spleen was attached to surrounding tissues. A total splenectomy was performed without opening the cyst. The patient had oral nutrition on the postoperative first day and he was discharged on the postoperative fifth day. There were no pathological findings at the patient's first month follow-up examination.

What is your diagnosis?

Metin Senol (✉), Hakan Özdemir, Zehra Ünal Özdemir, İbrahim Tayfun Şahiner
General Surgery, Nevşehir State Hospital, Nevşehir, Turkey
e-mail: drmetinsenol@gmail.com

Submitted/Gönderilme: 14.02.2014 Accepted/Kabul: 23.03.2014

ANSWER to PHOTO QUIZ

Hydatid cyst

Hydatid cysts are endemic especially in Mediterranean countries and in Southern Europe, South America and in Australia. Turkey is also an endemic region in terms of hydatid diseases. The frequency of hydatid cysts in our country has been reported as 1/2000 [1]. Although hydatid diseases have been described in almost every organ of the human body, approximately 70% of the cysts are situated in liver, followed by lungs (15%-47%) and rarely in spleen, brain, kidneys or bile ducts. Hydatid cysts are seldom seen in other organs or tissues in the absence of an involvement of the liver and lungs [1,2].

Non-parasitic cysts as well as parasiting ones should also be considered too in the differential diagnosis of splenic cysts. Especially, epidermoid and dermoid cysts should not be neglected. In addition to this, hemangiomas, lenfangiomas, spleen abscesses and cystic metastases should be kept in mind [3]. Ultrasonography is the most important noninvasive diagnostic method with a validity of around 90%. Although ultrasonography is as precise as CT, it is claimed that localization of the cyst, volume and relationships with peripheral organs are evaluated much better with CT [3,4].

Laboratory tests that are used in the diagnosis of hydatid diseases are the Indirect Haemagglutination Test (IHA), the Casoni Skin Test, the Weinberg Test, ELISA and Immunoelectrophoresis. Among these, the specificity of the most commonly used IHA test is between 90-100% and its sensitivity has been reported as 68.4% [5]. Medical treatment is given to patients before and after surgery and to patients with contraindications to surgery because of additional systemic diseases as well. Albendazol is frequently used in the medical treatment. When used preoperatively, it facilitates surgery by causing scoleces to lose their vitality, cysts to get smaller and to lose pressure and also decreases the risk of anaphylaxis [6].

Surgery is the primary treatment of splenic hydatid cysts. The surgical technique varies according to the patient, localization, number and size of the hydatid cysts. A total splenectomy can be undertaken without opening the cyst or spleen-preserving procedures can be used. Partial splenectomy or unroofing the cyst are the options for spleen-preserving procedures. A total splenectomy is recommended with cysts of an advanced size that are centrally located and close to splenic hilum. However, spleen-preserving surgery is recommended with young patients who have peripherally located cysts. Also in recent years, laparoscopic procedures and percutaneous drainages are being successfully performed to appropriate patients [7,8].

As a result, in the differential diagnosis of splenic cystic masses, hydatid cysts take the first place especially in endemic regions like Turkey. Patients may have no complaints until the cyst reaches an advanced size hindering the diagnosis, or patients may consult a doctor after facing complications as well. Radiological methods are important in diagnosis. The treatment of a splenic hydatid cyst is surgery and the type of surgery varies

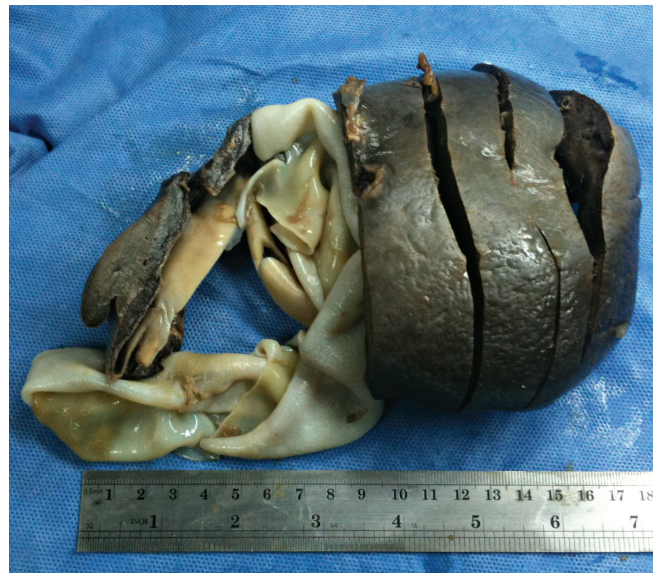

Figure 2: The splenectomy specimen including hydatid cyst and germinative membrane.

according to patient's age, his/her additional systemic diseases, localization, number and size of the cysts. Medical treatment is also applied in addition to surgery to facilitate the operation and decrease recurrences.

Conflict of Interest: The authors declare that there is no conflict of interests.

References

1. Hepgül G, Tihan D, Kocael P. Case report: primary splenic hydatidosis. *Turkish S Paras* 2010;34:184-6.
2. Fernandez-Ruiz M, Guerra-Vales JM, Enguita-Valls AB, Vila-Santos J, García-Borda FJ, Morales-Gutiérrez C. Splenic hydatid cyst, a rare location of extrahepatic echinococcosis: Report of six cases. *Eur J Intern Med* 2008;19:e51-3. doi: 10.1016/j.ejim.2008.02.003
3. Culafic DM, Kerkez MD. Spleen cystic echinococcosis: clinical manifestations and treatment. *Scan J Gastro* 2010;45:186-90.
4. el-Tahir MI, Omojola MF, Malatani T. Hydatid disease of the liver: evaluation of ultrasound and computed tomography. *Br J Radiol* 1992;65:390-2. doi: 10.1259/0007-1285-65-773-390.
5. Yardimci S, Ulas M, Surmelioglu A. Splenic recurrence of liver hydatid cyst and spleen preserving therapy. *Singapore Med J* 2011;52:223-5.
6. Bildik N, Cevik A, Altintas M. Efficacy of preoperative albendazole use according to months in hydatid cyst of the liver. *J Clin Gastro* 2007;41:312-6. doi: 10.1097/01.mcg.0000225572.50514.e6.
7. Dar MA, Shah OJ, Wani NA. Surgical management of splenic hydatidosis. *Surg Today* 2002;32:224-9.
8. Atmanzidis K, Papaziogas B, Mirelis C. Splenectomy versus spleen-preserving surgery for splenic echinococcosis. *Dig Surg* 2003;20:527-31.