

## Laparoscopic ureterolithotomy; which approach do you prefer?

Laparoskopik üreterolitotomi; siz hangi yolu tercih ediyorsunuz?

Cemil Aydın<sup>1</sup> , Ali Akkoc<sup>2</sup> 

<sup>1</sup> Hitit University, Department of Urology, Corum, Turkey

<sup>2</sup> Alanya Alaaddin Keykubat University, Department of Urology, Alanya, Turkey

### ÖZET

**Amaç:** Minimal invaziv üroloji prosedürlerinin gelişmesiyle, üreter taşlarının tedavisinde açık cerrahi girişimler daha az kullanılmaktadır. Laparoskopik üreterolitotomi (LU) endikasyonları şok dalgası litotripsi veya üreterorenoskopi ile tedavi edilemeyen büyük, çoklu ve / veya impakte üreter taşlarıdır. Bu çalışmada laparoskopik retroperitoneal ve transperitoneal üreterolitotomi tekniklerini karşılaştırmayı ve hangi prosedürün daha etkili olduğunu saptamayı amaçladık.

**Gereç ve Yöntemler:** Ocak 2012-Aralık 2017 tarihleri arasında büyük ve impakte üst üreter taş nedeniyle transperitoneal ve retroperitoneal LU uygulanan 45 hastayı değerlendirdik. Retroperitoneal ve transperitoneal yöntemler sırasıyla grup 1 ve grup 2 olarak sınıflandırıldı. Gruplar preoperatif, intraoperatif ve postoperatif klinik bulgulara göre karşılaştırıldı.

**Bulgular:** Gruplar arasında yaş, cinsiyet, taş büyüklüğü, kan kaybı ve vücut kitle indeksi açısından istatistiksel olarak anlamlı bir farklılık bulunmadı. Taşsızlık oranı her 2 grupta da %100 idi. VAS skorları grup 1'de istatistiksel olarak daha yüksek saptandı (p <0.05). Ortalama ameliyat süresi grup 2'de istatistiksel olarak daha kısa bulundu (p: 0.022). İntraoperatif hiçbir hastaya rutin double J stent konulmadı.

**Sonuçlar:** Transperitoneal yöntemle karşılaştırıldığında, retroperitoneal teknik, büyük ve impakte proksimal üreter taşlarının tedavisinde anlamlı olarak daha kısa ameliyat süresine ve daha az postoperatif ağrı oranına sahiptir.

**Anahtar Kelimeler:** Laparoskopi, transperitoneal, retroperitoneal, üreterolitotomi

### ABSTRACT

**Objectives:** With the improvement of minimally invasive urology procedures, open surgical interventions are less common to treat ureteral calculus. Laparoscopic ureterolithotomy (LU) indications are large multiple and/or impacted ureteral calculus that may not be treated with shock-wave lithotripsy or ureterorenoscopy approaches. We aimed to collate laparoscopic retroperitoneal and transperitoneal ureterolithotomy techniques and to identify which procedure is more effective.

**Material and Methods:** We reviewed 45 patients with large and impacted upper ureter calculus who underwent transperitoneal or retroperitoneal LU between January 2012 and December 2017. The retroperitoneal and transperitoneal routes were grouped as group 1 and 2, respectively. Groups were crosschecked according to preoperative, intraoperative, and postoperative clinical datum.


This study was approved by the Diyarbakır Gazi Yaşargil Research and Training- Clinical Research Ethical Committee (Approval number: 2016- 12/24, June 12). All research was performed in accordance with relevant guidelines/regulations, and informed consent was obtained from all participants.

**Corresponding Author:** Cemil Aydın, Hitit University, Kuzey Campus, Cevreyolu Bulv. 19030, Corum/Turkey

**GSM:** +90 364 219 19 19 **e-mail:** cemilaydin78@yahoo.com.tr

**Received:** May 3, 2020 - **Accepted:** June 22, 2020



This is an Open Access article distributed under the terms of the Creative Commons Attribution Non-Commercial License which permits unrestricted non-commercial use, distribution, and reproduction in any medium, provided the original work is properly cited. 

**Results:** We did not find statistically meaningful disparity between groups with regards to age, gender, stone size, blood loss and body mass index. The stone free accomplishment ratio was 100% in group 1 and 2. VAS scores were higher and statistically meaningful in group 1 ( $p < 0.05$ ). The mean operative time was statistically shorter in group 2 ( $p: 0.022$ ). No double J stent inserted routinely intraoperatively.

**Conclusion:** Compared to those obtained with the transperitoneal technique, the retroperitoneal technique has a significantly shorter operating time and less postoperative pain for large and impacted proximal ureteral calculus. More randomized, controlled and prospective studies on large samples are needed.

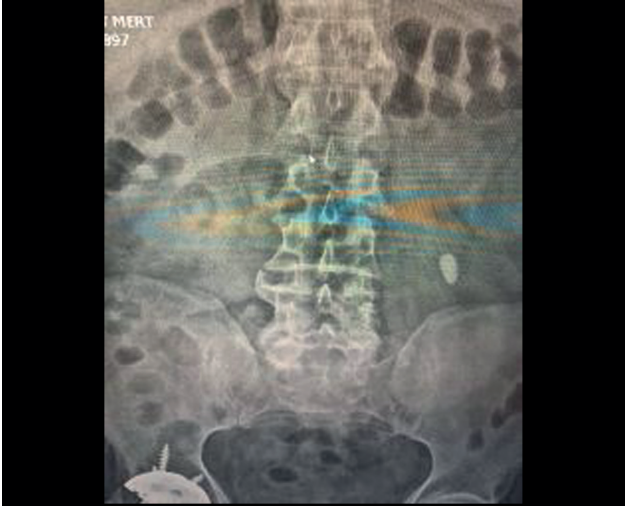**Keywords:** *Laparoscopy, transperitoneal, retroperitoneal, ureterolithotomy*

## INTRODUCTION

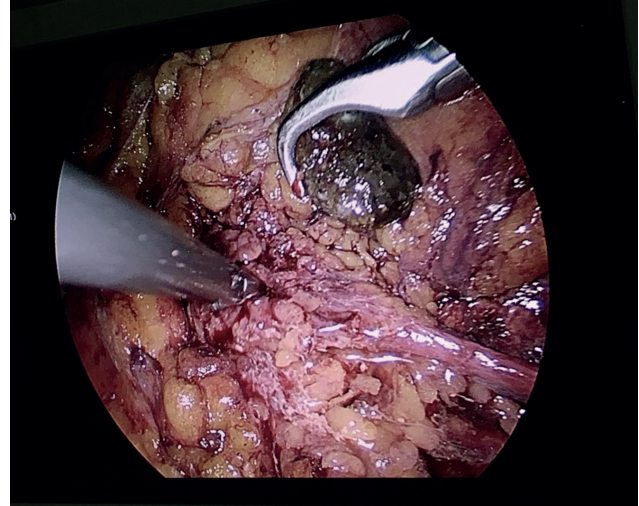
Urolithiasis is the third leading urological disease after urinary tract infection and prostate disorder. Shock wave lithotripsy (SWL) and ureterorenoscopy (URS) seem to be the first choice to treat ureteral calculus. With the improving of contemporary lithotripsy and URS techniques, open or laparoscopic surgical interventions are less common. However, the use of these techniques in proximal large ureteric stones is still contentious (1). URS is a minimally invasive option, but its effectiveness lowers, and complications ratio rises in proximal ureteral calculus larger than 2 cm (2). Laparoscopic and open ureterolithotomy indications are large multiple and/or impacted ureteral calculus that may not be treated with SWL or URS approaches (3). In the remedy of large/impacted ureter calculus, laparoscopic ureterolithotomy (LU) is generally opted technique because of its minimally invasive technique and high accomplishment ratio in one session. When compared to open approach, LU requires fewer analgesic, offers shorter hospital stays, promotes less blood loss, supports a shorter recovery time and is better cosmetically (4). For all of these reasons, LU is indicated for big impacted calculus when alternative minimally invasive options are unsuccessful. Proximal ureter calculus can be treated by two different laparoscopic techniques: transperitoneal and retroperitoneal. Both techniques have advantages and disadvantages (5,6). It is currently challenging to determine which technique should be selected to treat large ureteral stones, few studies compare these two techniques. So, we aimed in this study to crosscheck the complications and efficacy of transperitoneal laparoscopic ureterolithotomy (LTU) and retroperitoneal laparoscopic ureterolithotomy (LRU) in upper ureteral calculus larger than 15 mm.

## MATERIAL AND METHODS

The medical records of a total of forty-five patients with proximal impacted single radiopaque ureteral calculus who underwent LU at a tertiary academical clinic between January 2012 and December 2017 were gained from the hospital database and retrospectively analyzed. This study was approved by the Diyarbakır Gazi Yaşargil Research and Training- Clinical Research Ethical Committee (Approval number: 2016-12/24, June 12) and all patients signed consent forms. Our study also complied with the principles of the Declaration of Helsinki. Patients with calculi size larger than 15 mm were involved in the study. In addition, of 45 patients, 3 had a history of failed URS and 5 had a history of failed SWL. Calculus placed between the ureteropelvic joint and the pelvic part of the ureter were considered proximal ureteral stones. Distal ureteral stones, stones smaller than 15 mm, radiolucent calculus, patients under the age of 18, dysfunctional kidney units and patients with acute renal failure were excluded. Transperitoneal or retroperitoneal techniques were performed to each patient according to the surgeon's preference. Routine physical examination, coagulation test, blood biochemistry, full urine analysis, and urine culture were performed on all patients prior to the operation. Patients with urinary tract infection underwent surgical treatment after appropriate antibiotic treatment. Direct urinary system radiography (kidney, ureter, and bladder; KUB); ultrasonography (USG); non-contrast computed tomography (NCCT) were applied in all patients. Ureter calculus sizes were measured as the sum of maximal diameters of all stones on KUB (Figure 1). As previously stated, we grouped the transperitoneal and retroperitoneal techniques in this study as groups 1 and 2, respectively.



**Figure 1.** Preoperative image



**Figure 2.** Preoperative image

### **Transperitoneal Technique**

Under general anesthesia, pneumoperitoneum was composed using a Veress needle. After the first port was placed, it was placed by seeing two extra 10 mm ports. One additional port could be placed for liver retraction on the right side, if needed. We felt the calculi via an atraumatic grasper and, a Babcock clamp was utilized to estop calculus migration. Ureterotomy was applied with laparoscopic scissors, and the calculus was taken from the body using a tissue and organ removal bag (Figure 2). The ureterotomy line was sutured by a 4/0 polyglactin as an interrupted suture. The operative area was visually checked at the end of the procedure, then, a 16-18 Fr soft drain was placed, and the port sites were sutured.

### **Retroperitoneal Technique**

All patients were positioned at 90 degrees lateral decubitus under general anesthesia. A muscle-splitting incision of approximately 2-3 cm was applied at the Petit lumbar triangle. A retroperitoneal cavity was created by gentle index finger dissection. The operation space was created with a distention balloon. First, optic camera trocar was inserted then 10 mm and 5 mm trocars were inserted under direct visibility. The dissection of the ureter and the calculus remove techniques used were same to those performed in the transperitoneal procedure. The ureter incision was sutured by a 4/0 polyglactin as an interrupted suture. The operative area was visually checked at the end of the procedure, then, a 16-18 Fr soft drain was placed, and the port sites were sutured. No double J stents were inserted in both techniques routinely.

### **Postoperative Period**

On the first postoperative day, all patients were mobilized and KUB was taken. We removed the drain if the 24- hour drainage was less than 50 ml. Postoperative analgesia was not performed routinely; however, paracetamol (500 mg oral) and/or diclofenac sodium (75 mg intramuscular) were dispensed on patient request. Visual analogue scale (VAS) was recorded 3 hours after operation (VAS 0) and postoperative first day (VAS 1). The ureteral stents were removed within one month. Urine tests and serum creatinine were performed in the first postoperative month. We performed USG and/or NCCT between one to three months after the operation. Intraoperative-postoperative data and demographic data were enrolled. Complications were assessed as per Clavien-Dindo classification system (7).

### **Statistical Analysis**

IBM SPSS Statistics 22,0 (IL, Chicago, USA) were used for statistical analysis. Descriptive statistics (median, mean, frequency, standard deviation, and ratio) were used for evaluating the data. An independent sample t-test was used to collate normal distribution random variables and the Mann-Whitney U test was used for non-normally distributed variables. The qualitative data was collated by the Pearson test and the Fisher's exact test. In this study,  $P < 0.05$  was regarded statistically meaningful.

## RESULTS

Group 1 had 25 patients, and group 2 had 20 patients. Demographic data are shown in Table 1 for both groups. There was no statistically meaningful disparity in terms of age, sex, calculus size and side, and body mass index for both groups. In group 1, 72% (n:18) were males and 28% (n:7) were females, while in group 2, 30% (n:6) were females and 70% (n:14) were males. In group 1, 56% (n:14) of the calculus were in the right part and 44% (n:11) were in the left part, while in group 2, 50% (n:10) of the calculus were in the right part and 50% (n:10) were in the left part. The operative and postoperative data are shown in Table 2. There was no meaningful disparity between group 1 and group 2 regarding mean blood loss ( $65.60 \pm 22.15$  mL vs.  $67.20 \pm 16.48$  mL, respectively,  $p=0.458$ ). No patient needed blood transfusion. Our stone free accomplishment ratio was 100% in both groups. VAS scores were higher and statistically meaningful in group 1, after operation and first postoperative day (VAS0  $p < 0.001$  vs. VAS1  $p=0.002$ ). The average operative time was statistically shorter in group 2 (8120,01min,  $p=0.022$ ). None of the patients entailed intraoperative double J stent placement. Refer to Table 3 for data showing complications. No statistically meaningful disparity was observed between the groups regarding vascular injury ( $P= 1,000$ ) and postoperative fever ( $P= 1,000$ ). One patient in group 2 underwent open ureterolithotomy due to severe adhesion caused by periureteral inflammation and difficulty in ureter dissection. A long-time urine drainage was seen in four patients in group 2 after surgery. Although the prolonged urine drainage was finished in one patient on the fifth day after surgery, three patients required a double J stent insertion. One patient faced with prolonged urinary drainage in group 1 and resolved spontaneously in the sixth day. We observed ileus in 1 case in group 2 and 3 cases in group 1, and we managed with conservative treatment. In both groups, ureteral stenosis or severe ureteral hydronephrosis were not detected at the third month control by using USG, and/ or NCCT.

**Table 1.** Demographic Data

	Group 1 (n=25)	Group 2(n=20)	P
Mean age (y)	47,60±15,70	44,45±16,83	0,524 <sup>a</sup>
Sex (Male/Female)	18/7	14/6	0,883 <sup>b</sup>
Body Mass Index (kg/m <sup>2</sup> )	25,588±1,13	26,315±3,34	0,314 <sup>a</sup>
Stone size (mm)	18,22±1,36	18,21±1,56	0,966 <sup>a</sup>
Stone side (Right/Left)	14/11	10/10	0,688 <sup>b</sup>
Failed SWL (n)	1	4	0,090 <sup>c,*</sup>
Failed URS (n)	1	2	0,577 <sup>c</sup>

**a:** Independent-samples test.

**b:** Pearson  $\chi^2$  test.

**c:** Fisher's exact test.

**URS:** Ureterorenoscopy

**SWL:** Shock-wave lithotripsy

**\*P = .01.**

**Table 2.** Operative and Postoperative Data

	Group 1 (n=25)	Group 2(n=20)	P
Stone-free rate, (%)	100	100	-
Operative time (min)	94,72±18,14	81±20,01	0,22 <sup>b,**</sup>
Double -J stenting, n (%)	0	3 (15%)	0,080 <sup>a,*</sup>
Hospitalization mean $\pm$ SD (day)	4,40±1,33	3,82±1,48	0,076 <sup>d,*</sup>
Mean blood loss $\pm$ SD (ml)	65,60±22,15	67,20±16,48	0,458 <sup>b</sup>
VAS 0 mean $\pm$ SD	6,72±0,89	5,65±0,75	< 0,001 <sup>d,**</sup>
VAS 1 mean $\pm$ SD	5,36±0,91	4,35±0,93	0,002 <sup>d,**</sup>

Data are the mean [plus/minus] SD, unless otherwise stated

**a:** Independent-samples test.

**b:** Pearson  $\chi^2$  test.

**c:** Fisher's exact test.

**d:** Mann-Whitney U test.

**\*P = .01.**

**\*\*P = .05.**

**VAS:** Visual pain analog score



**Table 3.** Complications

	Group 1 (n=25)	Group 2(n=20)	P
Open conversion	0	1(5%)	0,444 <sup>a</sup>
Prolonged Urinary drainage	1 (4%)	4 (20%)	0,155 <sup>a</sup>
Ileus	3 (12%)	1 (5%)	0,617 <sup>a</sup>
Gonadal vein injury	1 (4%)	1 (5%)	1,000 <sup>a</sup>
Postoperative fever	1 (4%)	1 (5%)	1,000 <sup>a</sup>

<sup>a</sup>Fisher's exact test.

\*P =.01.

## DISCUSSION

Although, ureteral calculus are generally treated with URS or SWL, treatment hinges primarily on the size and location of the calculus, associated severity and period of pain, obstructed or non-obstructed drainage, and the charge and accessibility of the device (8). The laparoscopic surgery is suggested for larger than 1.5 cm, multiple or impacted ureteral calculus in which URS and ESWL were unsuccessful or are likely to be unsuccessful (9). Open surgery has the benefit of a superior-performance ratio in one period for such complex patients. However, laparoscopy, which is a minimally invasive surgery, is more preferred because it provides less analgesic use, short dated hospitalization, less patient blood wastage, shorter recovery duration, and better cosmesis than open surgery (4). LU could be exerted both thru the transperitoneal and retroperitoneal techniques. The first retroperitoneal ureterolithotomy was introduced in 1979 by Wickham (10), and Raboy implemented the first LTU in 1992 (11). The most important advantage of LU is that it is possible to extract the calculi in one session. Gaur et al. stated laparoscopic retroperitoneal ureterolithotomy in 12 patients with impacted and large calculus in the upper/middle ureter (12). They were successful in nine patients, but three patients necessitated conversion to open operation due to device problems and relative lack of laparoscopic experience (12). The superiority of the transperitoneal route is that it provides a wider operation area and suitable vision, and better identifiable anatomic landmarks (13). The hospital stay length and complications rate is lower in the retroperitoneal technique, but this technique provides a limited working area (14). In addition, retroperitoneal technique does not require colon mobilization and has a lower risk of visceral organ damage. The advantages of LRU include no bowel mobilization and lower postoperative ileus rate. Another advantage of LRU is that it could be easily applied in patients who have had prior abdominal operation history. Important features of the choice of retroperitoneal and transperitoneal methods are the surgeon's knowledge and choice (15). In agreement with the literature, the paralytic ileus rate, postoperative pain, and the VAS were meaningfully higher in group 1 in our study. We assume that, pain and ileus led to longer hospitalization for patients in group 1. In another study by Singh et al. reported retroperitoneal and transperitoneal laparoscopic ureterolithotomy in 48 patients who were separated into two groups, and they collated the demographic and clinical characteristics, and postoperative results in their cases (16). They reported that the transperitoneal technique caused more pain, the need for more analgesic, longer time ileus, and prolonged hospital stay collated to the retroperitoneal technique. They also found that the successfulness ratio of calculus taking was alike in both procedures. They stated that the retroperitoneal technique was more convenient for impacted large calculus in the proximal and middle part of the ureter (16). In most of the published literature, it has been reported that the laparoscopic retroperitoneal technique has a shorter postoperative recovery time (17). Retroperitoneal technique does not require bowel dissection and has a lower risk of visceral organ injury. In addition, when performing this technique, the risk of contamination of the peritoneal area and postoperative ileus rate are lower due to postoperative urine leakage (18). In the current research, the mean surgery time was statistically shorter in group 2, because it was easy to find the ureter, and there was no need for colon mobilization, peritoneal cavity contamination was inexistent, and there was no need for the dissection of solid visceral organs. In their study, Gaur et al. reported an average operation time of 79 minutes in 101 patients who experienced transperitoneal ureterolithotomy (12). Bove et al. declared that the average operation time of LTU was 75 minutes and that of LRU was 102 minutes (19). Singh et al. declared no statistically meaningful disparity between the LRU and LTU groups in 48 patients who underwent LU (16). The overall stone-free success

ratio following LU is generally 100%, and the conversion ratio to open operation is few (20). In our study, one patient required conversion to open surgery in group 2 due to intense sticking caused by periureteral inflammation and the unsuccessful ureteral dissection. Kaygısız et al. reported that the accomplishment rates of LU were high and retreatment rates were lower than URS (21). Their accomplishment ratios were 96.9 % and 65.5% after the first intervention for LU and URS, respectively. In their study, the LU surgery group had a higher accomplishment rate with longer operative time and hospital stay than the URS group (21). In the literature, routine ureteral stent placement after LU is still debatable and has very different opinions. Karami et al. compared patients with double J stents to patients void of double J stents, and declared that the presence of the double J stent considerably reduced the complication rates without increasing operation time (22). Bellman and Smith reported that if the urine is aseptic and the incision is minor, with a double J stent the defect will close spontaneously, incision suturing is not required (23). Hammady et al. reported that stentless LRU is safe, cost effective, has a short operation time, and does not require additional methods collated to LRU with the stent, which increases cost and inconvenience to the patient (24). Kijvikai and Patcharatrakul proposed the selective placement of double J stents in patients with ulceration, intense ureteral mucosal inflammation and improper stitching (25). We did not require any patients to insert double J stent intraoperatively. In our work, we placed double J stent in three patients due to prolonged urine drainage. Ureter stenosis is one of the major complications of LU. Noura et al, reported that the ureteral stricture rate was 2.5% (26). The etiology of postoperative ureteral stricture is not clearly known. Kijvikai and Patcharatrakul did not encounter ureteral stricture during the six-month follow-up in their cases with watertight suturing (25). In our study, we did not experience ureteral stenosis three months after surgery in both groups. The main limitations of our work are its retrospective nature, single-center work, small number of cases in both groups. More randomized, prospective trials with a greater count of cohorts are needed to determine which laparoscopic technique is effective and feasible in such cases.

## CONCLUSIONS

Laparoscopic ureterolithotomy provides rapid healing, high success rates in a single session and may be the primary therapy option in patients with large impacted ureteral calculus. The transperitoneal technique is more favorable than the retroperitoneal technique for surgeons with less experience in laparoscopic surgery because it ensures a larger working area, a more known anatomy, and more appropriate suturing. However, the transperitoneal technique is notably associated with ileus, pain, longer hospital stays and longer operation time. Significant aspects of transperitoneal and retroperitoneal methods selection depends on the surgeon's experience and preference.

**Ethical Approval:** This study was approved by the local ethical committee (Approval number: 2016-12/24). All research was performed in accordance with relevant guidelines/regulations, and informed consent was obtained from all participants.

## Financial Support and Sponsorship

None.

**Conflicts of Interest:** We declare that there was no conflict of interest.

## Contributors' Statements

Dr. CA; study design, drafting, reviewing, submission the final manuscript.

Dr. AA; data collection, statistical analysis, data collection at hospital information system, reviewing the manuscript, approved the final version of manuscript.

## REFERENCES

1. Lopes Neto A.C., Korkes F., Silva J.L., et al. Prospective randomized study of treatment of large proximal ureteral stones: extracorporeal shock wave lithotripsy versus ureterolithotripsy versus laparoscopy. J Urol 2012; 187:164-68.

2. Fang YQ, Qiu JG, Wang Dj, et al. Comparative study on ureteroscopic lithotripsy and laparoscopic ureterolithotomy for treatment of unilateral upper ureteral stones. *Acta Cir Bras* 2012;27:266-70.
3. Huri E, Basok EK, Ugurlu O, et al. Experiences in laparoscopic removal of upper ureteral stones: multicenter analysis of cases, based on the Turk Uro Lap Group. *J Endourol* 2010; 24:1279-82.
4. Tugcu V, Simsek A, Kargi T, et al. Retroperitoneal Laparoendoscopic single site ureterolithotomy versus conventional laparoscopic ureterolithotomy. *Urology* 2013;81:567-72.
5. Gaur DD, Trivedi S, Prabhudesai MR, et al. Laparoscopic ureterolithotomy: technical considerations and long-term follow-up. *BJU Int* 2002;89:339.
6. Khaladkar S, Modi J, Bhansali M, et al. Which is the best option to treat large (>1.5cm) midureteric calculi? J Laparoendoscopic? *Adv Surg Tech A* 2009;19:501-04.
7. Tefekli A, Karadag MA, Tepeler K, et al. Classifications of percutaneous nephrolithotomy complications using the modified Clavien grading system: looking for a standard. *Eur Urol* 2008; 53:184-90.
8. Rabani SM, Moosavizadeh A. Management of Large Proximal Ureteral Stones: A Comparative Clinical Trial Between Transureteral Lithotripsy (TUL) and Shock Wave lithotripsy (SWL). *Nephrourol Mon* 2012;4:556-9.
9. Türk C, Knoll T, Petrik A, Sarica K, Straub M, Seitz C: EAU Guidelines on Urolithiasis: 5.7 Open and laparoscopic surgery for removal of renal stones. *EAU Guideline, 2012*, pp 4748.
10. Wickham JEA (ed). The surgical treatment of renal lithiasis. In: *Urinary Calculus Disease*. New York: Churchill Livingstone 1979;145-98.
11. Raboy A, Ferzli GS, Ioffreda R, et al. Laparoscopic ureterolithotomy. *Urology* 1992;39:223-25.
12. Gaur DD: Retroperitoneal endoscopic ureterolithotomy: our experience in 12 patients. *J Endourol* 1993;7:501.
13. Harewood LM, Webb DR, Pope AJ. Laparoscopic ureterolithotomy: the results of an initial series, and an evaluation of its role in the management of ureteric calculi. *Br J Urol* 1994;74: 170-76.
14. McAllister M, Bhayani SB, Ong A, et al. Vena cava transection during retroperitoneoscopic nephrectomy: report of the complication and review of the literature. *J Urol* 2004;172:183-5.
15. Sancaktutar AA, Bozkurt Y, Atar M, et al. Urological laparoscopic surgery: Our experience of first 100 cases in Dicle University. *J Clin Exp Invest* 2012;3:44-8.
16. Singh V, Sinha RJ, Gupta DK, et al. Transperitoneal Versus Retroperitoneal Laparoscopic Ureterolithotomy: A Prospective Randomized Comparison Study. *J Urol* 2013;189:940-5.
17. Rofeim O, Yohannes P, Badlani G. Does laparoscopic ureterolithotomy replace shock-wave lithotripsy or ureteroscopy for ureteral stones? *Curr Opin Urol* 2001;11:287-91.
18. Feyaerts A, Rietbergen J, Navarra S, et al. Laparoscopic ureterolithotomy for ureteral calculi. *Eur Urol*. 2001; 40:609-613
19. Gaur DD, Rathi SS, Ravandale AV, et al. A single centre experience of retroperitoneoscopy using the balloon technique. *BJU Int* 2001;87:602-606.
20. Bove P, Micali S, Miano R, et al. Laparoscopic ureterolithotomy: a comparison between the transperitoneal and the retroperitoneal approach during the learning curve. *J Endourol* 2009; 23:953-7.
21. Flasko T, Holman E, Kovacs G, et al. Laparoscopic ureterolithotomy: the method of choice in selected cases. *JLaparoendoscAdvSurgTechA* 2005;15:149-52.
22. Kaygısız O, Coşkun B, Kılıçarslan H, et al. Comparison of Ureteroscopic Laser Lithotripsy with Laparoscopic Ureterolithotomy for Large Proximal and Mid-Ureter Stones *Urol Int* 2015; 94:205-09.
23. Karami H, Javanmard B, Hasanzadeh-Hadah A, et al. Is it necessary to place a Double J catheter after laparoscopic ureterolithotomy? A four-year experience. *J Endourol* 2012; 26:1183-86.
24. Bellman GC, Smith AD. Special considerations in the technique of laparoscopic ureterolithotomy. *J Urol* 1994;151:146-49.
25. Hammady A, Gamal WM, Zaki M, et al. Evaluation of ureteral stent placement after retroperitoneal laparoscopic ureterolithotomy for upper ureteral stone: randomized controlled study. *J Endourol* 2011;25:825.
26. Kijvikai K and Patcharatrakul S: Laparoscopic ureterolithotomy: its role and some controversial technical considerations: *Int J Urol* 2006;13:206.
27. Nouira Y, Kallel Y, Binous MY, et al. Laparoscopic retroperitoneal ureterolithotomy: initial experience and review of literature. *J Endourol* 2004;18:557-61.