

## An Uncommon Cause of Intestinal Obstruction: Paraduodenal Hernia

Esra Dişçi<sup>1</sup>, Mehmet İlhan Yıldırğan<sup>1</sup>, Yavuz Albayrak<sup>1</sup>, Ufuk Memiş<sup>2\*</sup>

<sup>1</sup>Department of General Surgery, Faculty of Medicine, Atatürk University, Erzurum, Turkey

<sup>2</sup>Department of General Surgery, Faculty of Medicine, Erzincan Binali Yıldırım University, Erzincan, Turkey

### Article History

Received 30 Oct 2020

Accepted 23 Dec 2020

Published Online 25 Jan 2021

### \*Corresponding Author

Dr. Ufuk Memiş

Department of Surgery,

Faculty of Medicine,

Erzincan Binali Yıldırım University,

Erzincan, Turkey,

Phone: +90 5354779004

E-mail: memisufuk@gmail.com

ORCID: <https://orcid.org/0000-0003-3393-3301>

**Abstract:** Internal hernias are defined as the herniation of the internal organs from a congenital or acquired cavity in the abdominal cavity. Paraduodenal hernias are a rare subgroup of internal hernias and causes 1% of small bowel obstruction. Paraduodenal hernias seen due to congenital malrotation of intestines. Herniated abdominal content locates in right or left retrocolic area. Although paraduodenal hernias seen rare, they should be kept in mind in the manner of differential diagnosis. In this article, we present case of a 52-year-old male patient who was admitted to the emergency department with the complaints of ileus and diagnosed as left paraduodenal hernia. © 2021 NTMS.

**Keywords:** Intestinal Obstruction, Small Bowel, Paraduodenal Hernia, Hernia.

## 1. Introduction

Paraduodenal hernias are rare causes of small bowel obstruction that constitutes approximately half of the internal hernias. Left paraduodenal hernias are three times more common than the right ones (1). Computed tomography (CT) is an important diagnostic tool in the preoperative evaluation of patients. Although it is difficult to consider paraduodenal hernias among the differential diagnosis, it is an important clinical presentation that may eventually lead to necrosis of the intestines. Contrast abdominal tomography is highly effective in aiding the diagnosis. In this article, we present case of a 52-year-old male patient who was admitted to the emergency department with the complaints of ileus and diagnosed as left paraduodenal hernia.

## 2. Material and Methods

### 2.1. Case

A 52-year-old male patient with abdominal pain, dyspepsia and vomiting symptoms exists for the last two days was admitted to the emergency service. He had previously undergone laparoscopic cholecystectomy and had long-term complaints of bloating and vomiting. On physical examination, there was minimal distension in the abdomen, without any muscular defense or rebound. In the laboratory tests white blood cell count was 7000/ $\mu$ L hemoglobin 15 g/dL. routine biochemistry and bleeding time values were within normal limits. Direct abdominal x-ray showed small bowel-type air-fluid levels. Contrast abdomen tomography showed that the small intestine was leveled and collected in an area such as in a sac (Figure 1a). Vascular structures in hernia sac extends to the hernia neck (Figure 1b).

Patient was hospitalized with the sac diagnosis of intestinal obstruction. During follow-up, his complaints did not regress and he was taken to the operation. The operation revealed that all small intestines were covered with a peritoneal membrane and herniated into the left paraduodenal space (Figure 2). The hernia sac was opened and intestines were mobilized. The blood supply to the intestines was normal. Peritoneal gap was closed (Figure 3). The patient was discharged on the postoperative 4<sup>th</sup> day.

### 3. Discussion

Internal hernias are defined as the herniation of the internal organ from a congenital or acquired cavity in the abdominal cavity. According to Hansmann and Morton's studies on 967 cases, the internal hernias are divided into 7 main types by their location: paraduodenal, foramen of Winslow, pericecal, intersigmoid, transmesenteric, transomental and retroanastomotic (2). In addition, Liew and colleagues identified 25 different internal hernias according to their anatomical location (3).

Paraduodenal hernias are a subgroup of internal hernias, constitute 50% of internal hernias and 1% of small bowel obstruction. Firstly Andrews pointed out the congenital malrotation occurred in paraduodenal hernias (4). Paraduodenal hernias are divided to two groups as right and left. In paraduodenal hernias, herniated abdominal content in retrocolic area named as fossa of Waldeyer at right, fossa of Landzert at left. Paraduodenal hernias are generally seen in the 4<sup>th</sup> and 5<sup>th</sup> decades of life, more frequent in males and occurs three times more commonly on the left side (5).

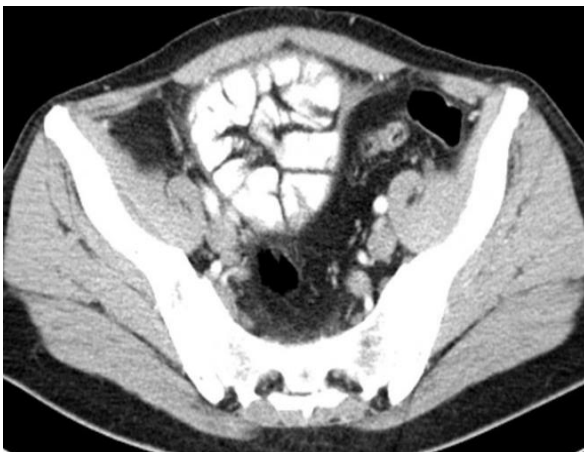Clinical manifestations include cramp-style pain, nausea, vomiting, distension, and clinical conditions ranging from ileus to shock due to herniated bowel segment. Until 50% of the patients are diagnosed, there

is a history of intermediate ileus and the other 50% group is diagnosed incidentally (6).

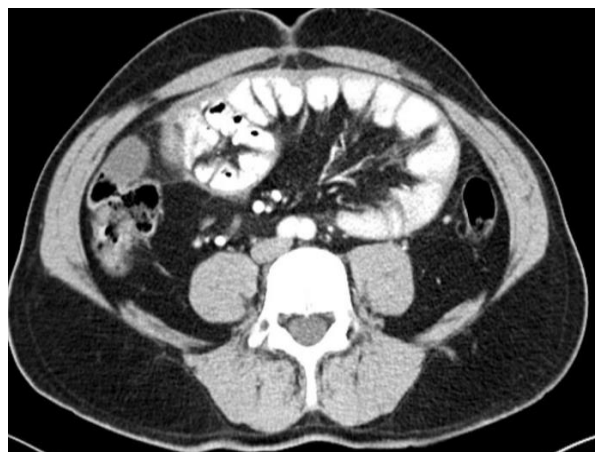
Radiological evaluation is very important in the diagnosis. Air-fluid levels can be seen at direct X-ray. In the barium examinations, dilated loops of small intestine at the proximal of the obstruction can be seen and slowed barium passage in the obstructed area can be noted. Arteriographs can show left deviation of jejunal or splenic artery. Ultrasonography may show an increase in thickness in small bowel walls or intraabdominal fluid. On computed tomography, the findings can be detected such as collecting the intestines form as mass without capsule and the right or left deviation of the veins at the level of the hernia neck (7). Although the imaging modalities are helpful, the findings of paraduodenal hernia were shaped within the framework of the 'Classic Empty Abdomen Sign' which was defined by Kummer in 1921 as the well-defined mass formed small intestines without passage of intestines to the real pelvis standing at upright position (8).

As surgical approach, open surgery technique is mostly used, but there are studies about laparoscopic approach (9). In operation, dilatation of the hernia neck or emptying of the content within the hernia sac with closure of the hernia neck can be applied. Additional surgical procedures may be required depending on the condition of the hernia. Since the hernia neck may be adjacent to right / left colic arteries, celiac artery and celiac vein, attention should be paid to the vascular structures mentioned above during the surgery (9). Left paraduodenal hernias should be treated surgically as soon as they are diagnosed since they have the risk of intestinal ischemia associated with obstruction and strangulation (10, 11).

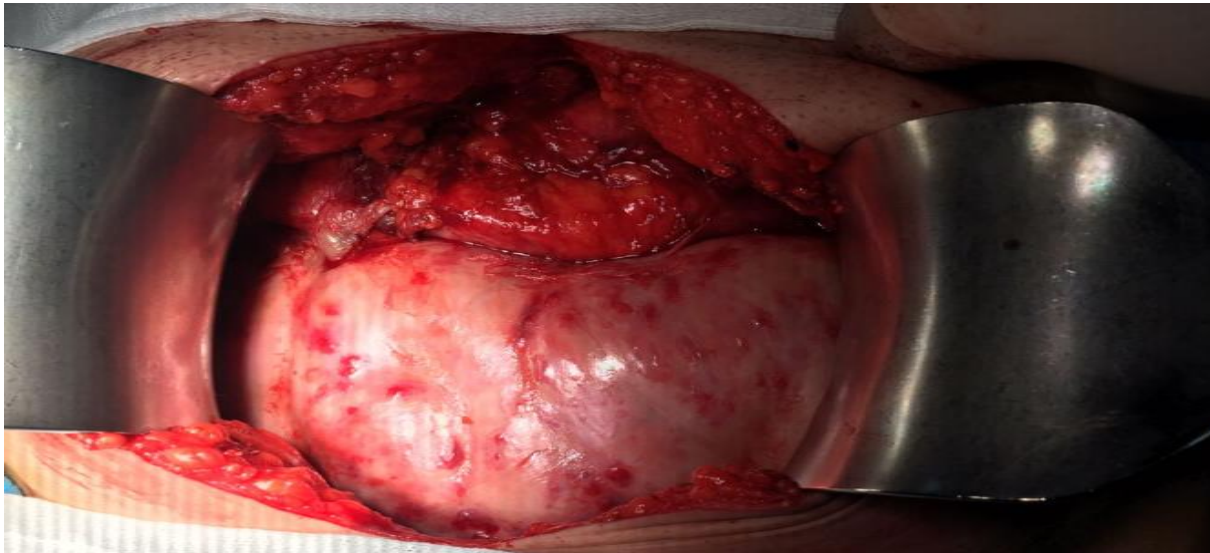
1a



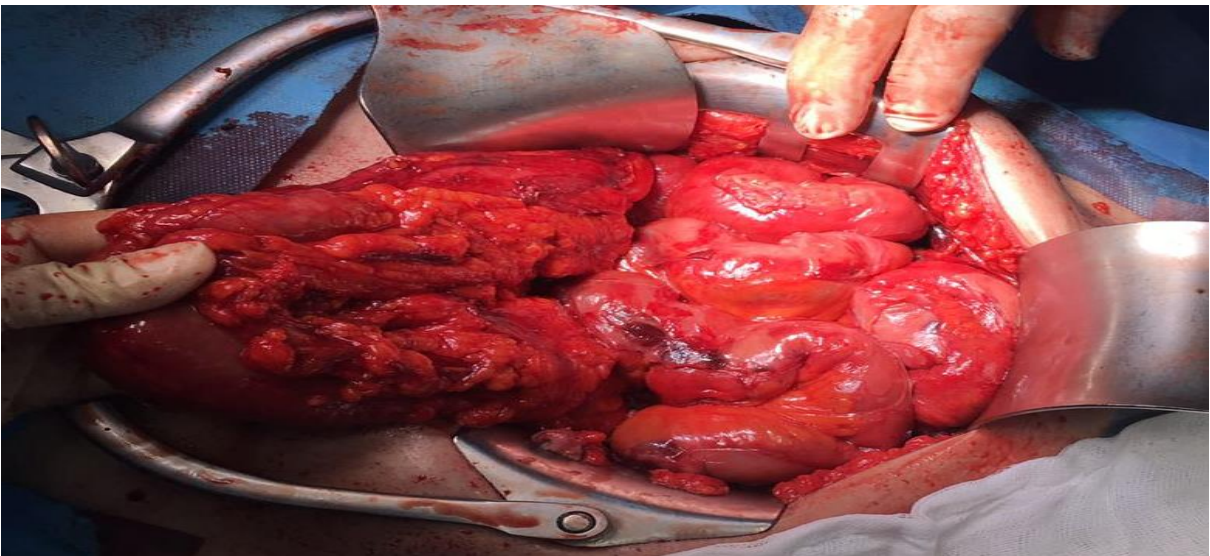
1b



**Figure 1:** Contrast abdomen tomography showing (a) leveling, enlargement of the small intestine and collection of the intestines in an area such as in the sac.,(b) vascular structures extending to hernia neck.



**Figure 2:** Intestines were covered with hernia sac.



**Figure 3:** After the hernia sac opened and intestines mobilized.

#### **Conflict of Interests**

The authors have no conflicts of interest to declare.

#### **Financial Support**

The authors declared that this study has received no financial support.

#### **Author Contributions**

Disci E, Yıldırğan M.İ., Albayrak Y. and Memis U. contributed to the conception and design of the study. Disci E and Memis U. contributed to data collection, literature review and writing of manuscript. Disci E, Yıldırğan M.İ., Albayrak Y. and Memis U. contributed to revising the work and final approval of the version.

#### **References**

1. Atasoy G, Temiz A, Albayrak Y, Yalcin A. A rare case of left paraduodenal hernia: A case report. *Arch Clin Exp Med* **2017**; 2(2): 55-57.
2. Hansmann GH, Morton SA Intraabdominal hernia: report of a case and review of the literature. *Arch Surg* **1939**; 3: 973-986.
3. Liew KL, Choong CS, Shiao GF, Yang WC, Su CM. Descending mesocolon defect herniation: case report. *Changgen Yi Xue Za Zhi* **1999**; 22: 133-137.
4. Andrews E, Duodenal Hernia, a Misnomer. *Surg Gynec Obstet* **1923**; 37: 740.
5. Manji R, Warnock GL Left paraduodenal hernia: an unusual cause of small-bowel obstruction. *Can J Surg* **2001**; 44: 455-457.
6. Huang YM, Chou AS, Wu YK, Wu CC, Lee MC, Chen HT, Chang YJ. Left paraduodenal hernia presenting as recurrent small bowel obstruction. *World J Gastroenterol* **2005**; 11: 6557-6559.
7. Blachar A, Federle MP, Dodson SF Internal hernia: clinical and imaging findings in 17 patients with emphasis on CT criteria. *Radiology* **2001**; 218: 68-74.
8. Kummer E Signes radiologiques de la hernie interne duodenojejunaie. *J Radiol Electrol* **1921**; 5: 362-368.

9. Parmar BPS, Parmar RS Laparoscopic management of left paraduodenal hernia. *J Min Access Surg* **2010**; 6(4): 122-124.
10. Al-khyatt W, Aggarwal S, Birchall J, Rowlands TE. Acute intestinal obstruction secondary to left paraduodenal hernia: a case report and literature review. *World J Emerg Surg* **2013**; 8: 5.
11. Işık A. et al.:How could such a wide piece of tree root pass through the narrow pyloric orifice? An extremely rare case, *Am J Case Rep* **2014**; 15: 284-287.

**Authors' ORCID**

Esra Dişçi

<http://orcid.org/0000-0003-3657-3620>

Mehmet İlhan Yıldırım

<https://orcid.org/0000-0002-9041-9352>

Yavuz Albayrak

<http://orcid.org/0000-0002-2535-4329>

Ufuk Memiş

<http://orcid.org/0000-0003-3393-3301><https://dergipark.org.tr/tr/pub/ntms>

All Rights Reserved. © 2021 NTMS