

## ORIGINAL ARTICLE

# Results of Plate Osteosynthesis with Deltopectoral Approach for Proximal Humerus Fractures

## Proksimal Humerus Kırıklarında Deltopektoral Yaklaşımla Plak Osteosentez Sonuçları

<sup>1</sup>Tank Altunkılıç <sup>1</sup>Malatya Turgut Ozal University Faculty of Medicine, Department of Orthopedics and Traumatology, Malatya, Türkiye.**Correspondence**

Malatya Turgut Ozal University Faculty of Medicine, Department of Orthopedics and Traumatology, Türkiye

**E-Mail:** [tarik.altunkilic@ozal.edu.tr](mailto:tarik.altunkilic@ozal.edu.tr)**How to cite ?**

Altunkılıç T. Results of Plate Osteosynthesis with Deltopectoral Approach for Proximal Humerus Fractures. Genel Tıp Dergisi. 2023; 33(3):249-254.

**ABSTRACT****Aim:** The aim of this study is to evaluate the functional and radiological results of patients who underwent plate osteosynthesis with the deltopectoral approach in proximal humerus fractures, according to the intact shoulder.**Materials and Methods:** Our study included 33 patients who underwent proximal humeral anatomic locking plate with deltopectoral approach due to proximal humeral fracture (PHF) between 2015 and 2017. Patients over 18 years of age, with closed humeral fractures, and with intact contralateral humerus and shoulder were included in our retrospective study. The functional results between the operated and healthy sides of the patients were evaluated by comparing the Constant-Murley score and radiological results with the full anteroposterior radiography and the collodiaphyseal angles.**Results:** According to the Constant Murley scoring categorical data structure of the patients, the operated side was 6.1% (n=2) poor, 6.1% (n=2) moderate, 39.4% (n=13) good, 48.5% (n=16) excellent, while the healthy side was %. The results were 0% (n=0) poor, 3% (n=1) moderate, 30.3% (n=10) good, and 66.7% (n=22) excellent. According to the Constant Murley scoring categorical data structure, a statistical difference was found between the operated side and the healthy side (p>0.05). While the mean Constant Murley score of the operated side was 85.82 ± 7.07, the mean Constant Murley score of the healthy side was 90.67 ± 5.76. While the average of the collodiaphyseal angles of the operated side was 130.03± 4.64; the mean of the angles of the intact side was 135.64 ± 5.04. In terms of Constant Murley shoulder scores and collodiaphyseal angle values of the patients; a statistical difference was observed between the operated sides and the healthy sides (p<0.05).**Conclusion:** It has been observed that both clinical and functional results of the patients were successful after plate osteosynthesis using the deltopectoral approach and proximal humerus anatomical locking plate in proximal humerus fractures.**Keywords:** Proximal humerus fracture, Deltopectoral approach, Plate osteosynthesis**ÖZ****Amaç:** Proksimal humerus kırıklarında deltopektoral yaklaşım ile plakosteosentez yapılan hastaların sağlam omuzuna göre fonksiyonel ve radyolojik sonuçlarının değerlendirilmesi amaçlanmıştır.**Gereç ve Yöntemler:** Bu çalışmaya Ocak 2015-Ocak 2017 tarihlerinde proksimal humerus kırığı (PHK) nedeniyle deltopektoral yaklaşım ile proksimal humerus anatomik kilitle plak uygulanan 33 hasta dâhil edildi. Retrospektif çalışmamıza 18 yaş üstü, kapalı humerus kırığı olan, kontralateral humerusu ve omuzu sağlam olan hastalar alınmıştır. Hastaların ameliyatlı ve sağlam taraflar arası fonksiyonel sonuçları Constant-Murley skorunun ve radyolojik sonuçları tam anteroposterior grafi ile kollodiyafer açılarının karşılaştırılması ile değerlendirildi.**Bulgular:** Hastalarda Constant Murley skorlama kategorik veri yapısına göre ameliyatlı taraf %6.1 (n=2) kötü, %6.1 (n=2) orta, %39.4 (n=13) iyi ve %48.5 (n=16) mükemmel iken, sağlam taraf %0 (n=0) kötü, %3 (n=1) orta, %30.3 (n=10) iyi ve %66.7 (n=22) mükemmel sonuç elde edildi. Hastalarda Constant Murley skorlama kategorik veri yapısına göre ameliyat edilen taraf ile sağlam taraf arasında istatistiksel bir fark tespit edilmiştir (p>0.05). Ameliyatlı tarafın Constant Murley skoru ortalaması 85,82 ± 7,07 iken, sağlam tarafın Constant Murley skoru ortalaması 90,67 ± 5,76 idi. Ameliyatlı tarafın kollodiyafer açıları ortalaması 130,03± 4,64 iken; sağlam tarafın açıların ortalaması 135,64 ± 5,04 'tür. Hastaların Constant Murley omuz skorları ve kollodiyafer açısı değerleri açısından; ameliyat edilen taraf ile sağlam taraf arasında istatistiksel bir farklılık gözlemlendi (p<0,05).**Sonuç:** Proksimal humerus kırıklarında deltopektoral yaklaşım ile proksimal humerus anatomik kilitle plak kullanılarak yapılan plakosteosentez sonrası hastaların hem klinik hemde fonksiyonel sonuçlarının başarılı olduğu görülmüştür.**Anahtar Kelimeler:** Proksimal humerus kırığı, Deltopektoral yaklaşım, Plakosteosentez**Introduction**

Proximal humeral fracture (PHF) increases with aging and is one of the most common fractures in the elderly (1,2). It constitutes 5% of all fractures (3). In the treatment of these fractures, patient satisfaction is high in conservative treatment, and surgery is used as an option according to the translation and angulation of the fracture fragments (4,5). Conservative treatments may include a velpau bandage, arm sling, or cast with shoulder support. Plate osteosynthesis, intramedullary

nailling, and arthroplasty can be counted among the surgical options, but the treatment may vary according to the age of the patient and the type of fracture (6).

The most commonly used implant in the surgical treatment of PHF is the proximal humerus anatomical locking plates (PHALP). The most important advantages of these plates are; Thanks to its low profile, it reduces

soft tissue damage, can be screwed at different angles, and Kirschner wire holes in the proximal of the plate can be used to fix rotator muscle tears (7).

PHF surgical approaches include deltopectoral approach, anterolateral acromial approach, limited deltoid splitting, and percutaneous approach. Among them, the deltopectoral approach is the most preferred surgical approach among surgeons because of its successful clinical results (8,9). We used the deltopectoral approach in our study.

In our study, we aimed to evaluate the functional and radiological results of patients who underwent plate osteosynthesis with the deltopectoral approach in proximal humerus fractures compared to the intact shoulder.

### Materials and Methods

Thirty-three patients who were diagnosed with proximal humeral fracture (PHF) between January 2015 and January 2017 and underwent proximal humeral anatomical locking plate (PHALP) with the deltopectoral approach were included in this study.

PHF are 80% nondisplaced fractures and do not require surgery. These are 80% curable with non-surgical early intervention and rehabilitation. In general, conservative treatment is recommended for phk displaced less than 1 cm and angulation less than 45 degrees. Osteosynthesis indications include displaced tubercle fractures of more than 5 mm, Neer 3-4 fragmented fractures, Surgical neck Neer 2 fragmented fractures, Fractured dislocations.

Patients over 18 years of age, with closed humeral fractures, and with intact contralateral humerus and shoulder were included in our retrospective study. Our study did not include Patients with pathological fractures, fracture-dislocations, possible neural damage, fractures of the scapula or humerus shaft, or distal and proximal humeral joint fractures such as the elbow joint. The results of the patients were compared with the Constant-Murley score (6th month), and the radiographic results (6th month) were compared by measuring the collodiaphyseal angles on the full anteroposterior radiograph. The fracture classification of the patients was made according to the AO/OTA classification (8). The study was conducted in accordance with the principles of the Declaration of Helsinki and was approved by the Ethical Committee of Malatya Turgut Ozal University Ethics Committee (Approval Date: 29.03.2022, Session No: 2022/11).

### Surgical application

All of the patients underwent general anesthesia and the operation was performed by drawing the landmarks in the chaise lounge position (Figure 1). Incision was made with deltopectoral approach in all patients. In the deltopectoral approach, an approximately 10 cm incision was made from the coracoid process towards the deltoid insertion. The cephalic vein in the deltopectoral space was preserved. A Hohmann retractor was placed under

the deltoid just lateral to the acromion. The other Hohmann was placed below the deltoid along the humeral shaft, and the third was located just distal medially to the subscapularis tendon. In order to reach the fracture parts, it was tried to reach by preserving the soft tissue structures. Fracture fragments were reduced in accordance with the anatomical structure and PHALP was placed in accordance with the intact shoulder collodiaphyseal angle (Figure 2). Rotator cuff tears were sutured with Ethibond suture with the help of Kirschner wire holes in the proximal plate. Fracture reduction and collodiaphyseal angle were evaluated with intraoperative C-arm fluoroscopy. The wound was closed without placing a hemovac drain. Velpau bandage was applied. ROM exercises were started on the 3rd postoperative day. The patients were discharged on the 5th postoperative day if there were no complications. On the 15th postoperative day, the sutures of the patients were removed and physical therapy was started.

Radiographic results were evaluated by comparing the anteroposterior radiography with the collodiaphyseal angles. In the collodiaphyseal angle measurement, the line drawn parallel to the articular surface of the humeral head and the line passing through the middle of the humeral head were drawn perpendicular to each other. The angle between the line passing through the humeral head and the line passing through the midline of the humeral shaft was accepted as the collodiaphyseal angle (Figure 3). In the preoperative period, the collodiaphyseal angle of the healthy side was measured, and the collodiaphyseal angle of the fractured side was corrected according to the angle of the intact side in the intraoperative period.

Functional results between the operated and healthy sides were evaluated with the Constant-Murley score. The Constant-Murley score (CMS) is used to monitor limb function after shoulder surgery (10). It is a 100-point scale. Scoring consists of four parts. It consists of pain, strength, activities of daily living and range of motion. It is seen that the scoring is high in patients with good shoulder functions (11).

**Statistical analyzes:** The analyzes obtained in our study were examined with the SPSS (Statistical Program in Social Sciences) 25 program. The compatibility of the data with normal distribution was checked with the Kolmogorov Smirnov Test (12). The significance level ( $p$ ) for comparison tests was accepted as 0.05. Since the distribution of the variables was normal ( $p > 0.05$ ), statistical analysis was performed using parametric test methods. Comparisons in paired groups; The significance test of the difference between the two means (two independent samples  $t$  test) was performed. In the evaluation of categorical data, the chi-square ( $\chi^2$ ) test was performed by creating cross tables.

### Results

In this study, 5 of the patients were proximal: A2, 11 A3, 7 B1, 4 B2, 6 C2, according to the AO/OTA classification

between January 2015 and January 2017. Thirty-three patients who underwent PHALP with deltopectoral approach for humeral fracture (PHF) were included. The demographic information of the patients, the mechanism of injury and additional pathologies are shown in Table 1. Two of the patients (6%) had both proximal humeral fractures and fractures extending to the distal shaft. In these two patients, double plate osteocentesis was performed by extending the incision with a distally lateral approach. Rotator cusp rupture was present in 5 patients (15%) and were sutured using plate holes.

The mean age of the patients was  $45.7 \pm 13.47$ , the follow-up period was  $7.36 \pm 1.67$  months, the intraoperative blood loss was  $17.85 \pm 3.37$  ml, and the time of union was  $16.15 \pm 2.79$  weeks.

It was tested whether there was a correlation between the Constant-Murly scores (excellent, good, moderate, poor) between the operated side and the healthy side in the participants included in the study, and the results are shown in Table 2. According to the Constant-Murly scores of the participants included in the study, there was no statistically significant relationship between the operated side and the healthy side ( $p > 0.05$ , Table 2).

A statistically significant difference was found between the operated side and the healthy side according to the Constant-Murly scores and collodiaphyseal angle values in the participants included in the study ( $p < 0.05$ , Table 3).

In the patient controls, deep infection developed in 1 (3%) patient 3 months later and the plaque was removed. Avascular necrosis (AVN) and nonunion developed in this patient. One (3%) patient union was with minor varus deformity. No valgus deformity was found in the patients. Impingement syndrome was not observed in any patient.

**Table 1:** Demographic and General features

Variable	Group	Number of patients	Percent
Gender	Male	18	54.5
	Female	15	45.5
Side	Right	17	51.5
	Left	16	48.5
Injury Mechanism	Traffic accident	10	30.3
	Fall	23	69.7
	No Additional Pathology	28	84.8
Additional Pathology	Femur Fracture	1	3.0
	Tibia Fracture	1	3.0
	Forearm Fracture	1	3.0
	Rib Fracture	2	6.1

**Table 2:** Relationship Between Operated Side and Intact Side According to Constant-Murly Scores

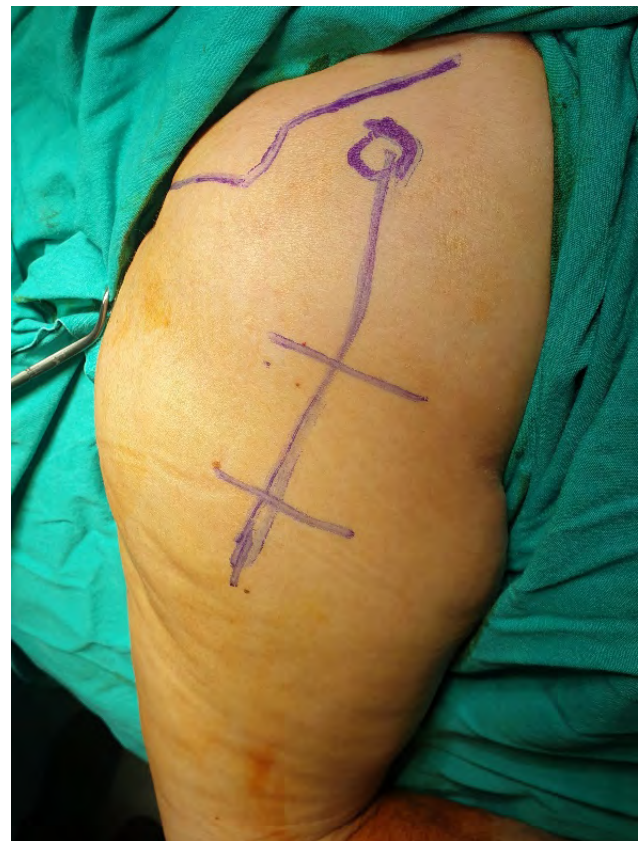Variable	Group	Group		Total	P value
		Intact Side	Operated Side		
Constant-Murly Scores	Excellent	No	22	16	38
		Percent	66.7	48.5	57.6
	Good	No	10	13	23
		Percent	30.3	39.4	34.8
	Moderate	No	1	2	3
		Percent	3.0	6.1	4.5
Poor	No	0	2	2	
	Percent	0.0	6.1	3.0	

p; Chi-square ( $\chi^2$ ) test statistic significance value, No: Number of patients

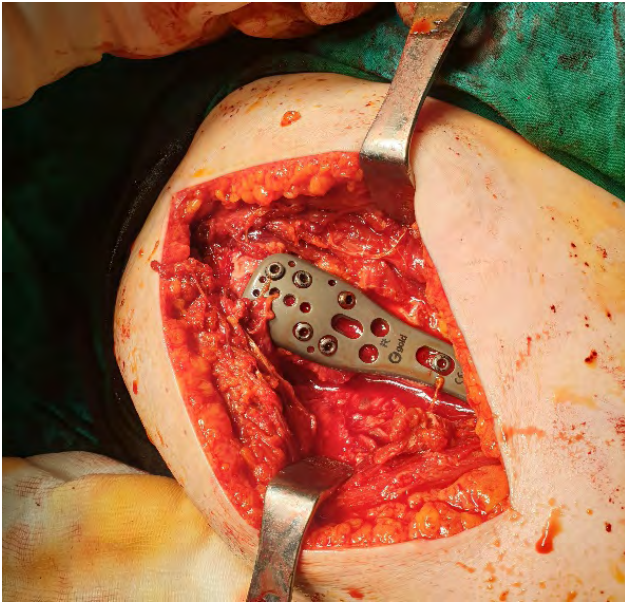
**Table 3:** Comparison of Operated and Healthy Sides According to Constant-Murley Scores and Collodiaphyseal Angle Values

Variable	Group	Mean $\pm$ ss	Test value	P value
Constant-Murly Scores	Intact Side	$90.67 \pm 5.76$	3.052	0.003*
	Operated Side	$85.82 \pm 7.07$		
Collodiaphyseal Angle	Intact Side	$135.64 \pm 5.04$	5.848	0.001*
	Operated Side	$128.3 \pm 5.15$		

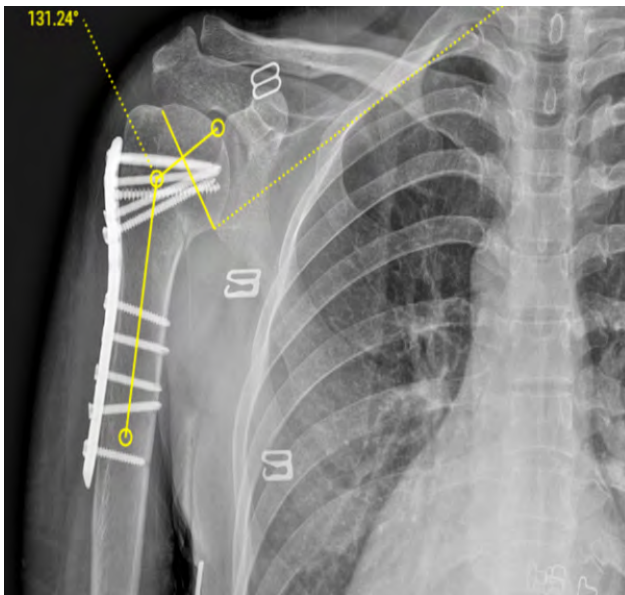
ss; standard deviation, Test; Significance Test Value of the difference between the two means, \* $p < 0.05$ . There is a statistically significant difference between the groups.



**Figure 1:** Incision site



**Figure 2:** Plate osteosynthesis



**Figure 3:** Postoperative collodiaphyseal angle measurement

## Discussion

80% of patients diagnosed with PHF are treated conservatively, and surgical treatment is recommended for only 20% (13). Although the indication criteria for surgical treatment in PHF vary, it is recommended especially for displaced fractures with more than two comminuted fractures (14). They stated that open reduction and plate osteosynthesis are the most commonly used surgical treatments (14).

In the study of Vajara et al., 30 patients with PHF were operated with deltopectoral opening. The mean Constant scores were 84; 47% (14) excellent, 37% (11) good, 13% (4) moderate, 3% (1) poor. Mean Constant scores were 84; 14 patients excellent, 11 patients good,

4 patients moderate, 1 poor (15). In the study of Khan et al., For functional outcomes, 19(12.41%) patients had poor results, 30(19.60%) had fair results, 37(24.18%) had good results and 67(43.79%) had excellent results (16). In our study, in the comparison of the categorical (excellent, good, moderate, bad) data structure of the Constant-Murly score, it was determined that the number of excellent and good patients on the healthy side was 32, and the number of excellent and good patients on the operated side was 29 (Table 2). It was observed that the patients whose condition was determined as moderate and bad in the intact shoulder were 1 person, and the patients whose condition was determined as moderate and bad on the operated side were 4 people. It was determined that the number of patients with satisfaction observed on the operated side was 29. According to the Constant-Murly scores of the patients included in the study, no statistically significant relationship was found between the operated side and the healthy side ( $p>0.05$ , Table 2). This shows that a functional result close to a healthy shoulder was achieved in our study.

In the study of Kavuri et al., 4.6% avascular necrosis and 1.5% nonunion were detected (17). In some studies, nonunion after open reduction and internal fixation (ARIF) has been reported in 12% to 34% of proximal humerus three-part fractures and 41-59% of four-part fractures (18-21). In the study of Peter et al., 4 of 16 patients developed nonunion (22). In our study, AVN (secondary to infection) developed in 1 (3.3%) patient.

In the study of Joon et al., the postoperative neck-shaft angle of patients who underwent platyosteocentesis with the deltopectoral approach was  $132.9 \pm 8.7$  (23). Wang et al. reported that complications could be reduced, shoulder function could be improved, and better postoperative outcome could be achieved in patients who underwent open reduction and platyosteocentesis with postoperative neck-shaft angle greater than  $127^\circ$  (24). In our study, the neck-shaft angle averaged  $130.03 \pm 4.64$  degrees. In the study of Vajara et al., a comparison of head shaft angle at immediate post-operatively with final follow up, 73% (22) was in normal range between 125-145 degrees which 1 case had secondary change into minor varus, bone quality and stability of the whole construction. The skin sutures are removed after 2 weeks. Elbow, wrist and hand motion are encouraged initially. Results of Proximal Humeral Fracture Fixation with Anatomical Locking Compression Plate using 6 stepwise Intraoperative Criteria in Surgical Procedures: a Retrospective Study. 17%(5) minor varus initially, 3%(1) minor valgus, 7% (2) major valgus (15). In our study, union in minor varus deformity was observed in 1 (3%) patient. No valgus deformity was found. As a result of our study, it was observed that the shoulder functions were better as the head-neck angle of the fractured extremity approached the head-neck angle of the intact extremity.

Thompson et al. reported that the success rate in Deltopectoral open reduction and internal fixation in fractures is high (25). Rouleau et al. compared the deltopectoral and deltoid split approaches in Neer type 2 and 3 fractures in their study (26). It was observed that the deltopectoral approach had better functional results compared to the deltoid split approach in proximal humerus neer 2 and 3 fractures that underwent locked-plate osteocentesis (26). The data obtained in Rouleau's study were in favor of the deltopectoral approach (26). In our study, functional results close to a healthy shoulder were obtained in patients who underwent deltopectoral approach.

**Limitations:** The limitations of our study can be counted as; a small number of patients, the absence of a comparative group with other surgical approaches and implants, and the short follow-up period.

**Conclusion:** As a result, it was observed that both clinical and functional results of the patients were successful after plate osteosynthesis performed using the deltopectoral approach and proximal humerus anatomical locking plate in proximal humerus fractures. In addition, thanks to the fact that locking screws can be applied to the proximal humerus locked anatomical plates and there are holes that allow us to suture the rotator cuff tears; It provides stability that can allow shoulder movement in the early period and helps patients gain a function close to their healthy shoulder. The deltopectoral approach, on the other hand, allows us to evaluate the anatomy of both the fracture and the rotator cuff, thanks to the wide surgical field it provides for proximal humeral fractures, and facilitates our intervention in proximal humeral fractures extending distally.

**Ethic:** In this study, national and international ethical rules are observed.

**Ethic Board:** This research protocol was approved by Malatya Turgut Ozal University Ethics Committee (Approval Date: 29.03.2022, Session: 2022/11).

**Conflict of Interest:** No conflict of interest was declared by the authors.

**Financial Disclosure:** The authors declared that this study has received no financial support.

**Acknowledgment:** Thanks to Malatya Turgut Ozal University Faculty of Medicine, Department of Orthopedics and Traumatology, for their contribution.

**Declaration of Congress Abstract:** Our study was presented at the Bone Joint 2021 congress organized by the Bone and Joint Surgery Association between 13-16 October 2021. An oral presentation of our study was made.

## References

- Lauritzen B, Schwarz P, Lund B, et al. Changing the incidence and residual lifetime risk of fractures associated with extensive osteoporosis. *Osteoporosis Int.* 1993;3:127-132.
- Palvanen M, Kannus P, Niemi S, Jari Parkkari, P McNair, I Transbøl . Update on the epidemiology of proximal humeral fractures. *Clin Orthop Relat Res.* 2006;442:87-92.
- Horak J, Nilsson BE et al. Epidemiology of fracture of the upper end of the humerus. *Clin Orthop Relat Res.* 1975;(112):250-253.
- Gaebler C, McQueen MM, Court-Brown CM. Minimally displaced proximal humerus fractures: epidemiology and outcome in 507 cases. *Acta Orthopedic Screening.* 2003; 74: 580-585.
- Pinkas D, Wanich TS, DePalma AA, Konrad I Gruson. Misunion management of the proximal humerus: current concepts. *J Am Acad Orthopedic Surgery.* 2014; 22: 491-502.
- Kannus P, Palvanen M, Niemi S, J Parkkari, M Järvinen, Ben Vuori. Osteoporotic fractures of the proximal humerus in elderly Finnish persons: sharp increase in 1970-1998 and alarming projections for the new millennium. *Acta Orthop Scand.* 2000;71:465-470.
- Vijayvargia M, Pathak A, Gaur S. Outcome analysis of Locking Plate Fixation in Proximal Humerus Fracture. *J Clin Diagn Res.* 2016;10:01-5.
- Buecking B, Mohr J, Bockmann B, Ralph Zettl, Steffen Ruchholtz. Deltoid-split or Deltopectoral Approaches in the Treatment of Displaced Proximal Humerus Fractures? *Clin Orthop Relat Res.* 2014; 472:1576-1585.
- Brunner F, Sommer C, Bahrs C, Rainer Heuwinkel, Christian Hafner, Paavo Rillmann, et al. Open reduction and internal fixation of proximal humeral fractures using a proximal humeral locking plate: a prospective multicenter analysis. *J Ortop trauma.* 2009;23:163-172.
- VB Conboy, RW Morris, J Kiss, A J Carr. "An assessment of the continuous Murley shoulder assessment"; *J Bone Joint Surgery.* 1996;78-B:229-232.
- MT Hirschmann, B. Wind, Felix Amsler, Thomas Gross; "Reliability of Measurement of Shoulder Abduction Strength for the Constant-Murley Score"; *Clin Orthop Relat Res.* 2010; 468; 1565-1571.
- Alpar, R, Applied Statistics and Validity-Reliability with Examples in Sports, Health and Education Sciences, 6th Edition, Detay Publishing, Ankara 2020; 147
- Egol KA, Ong CC, Walsh M, Laith M Jazrawi, Nirmal C Tejwani, Joseph D Zuckerman. Early complications in proximal humerus fractures (OTA Types 11) treated with locked plates. *J Orthop Trauma.* 2008;22:159-164.
- Gardner MJ, Voos JE, Wanich T, David L Kask , Dean G Lorich. Vascular implications of minimally invasive plating of proximal humerus fractures. *J Orthop Trauma.* 2006;20:602-607.
- Vajara Phipobmongkol, Suhum Ngamkittidechakul, Suthorn Bavonratanavech, Results of Proximal Humeral Fracture Fixation with Anatomical Locking Compression Plate using 6 stepwise Intraoperative Criteria in Surgical Procedures: A Retrospective Study. *The Bangkok Medical Journal.* 2006;12.
- Khan, I., Zeb, J., Khan, Q., Zafar, H., & Khan, M. S. Functional outcome of PHILoS plate fixation in proximal humeral fractures. *Rawal Medical Journal.* 2021;46: 348-348.
- Kavuri, V., Bowden, B., Kumar, N., Doug C. Complications Associated with Locking Plate of Proximal Humerus Fractures. *IJOO.* 2018; 52;:108-116.
- Flatow EL, Cuomo F, Maday MG, S R Miller, S J McIlveen, L U Bigliani. Open reduction and internal fixation of two-part displaced fractures of the greater tuberosity of the proximal part of the humerus. *J Bone Joint Surg Am.* 1991;73:1213-1218.
- Hawkins RJ, Bell RH, Gurr K. The three-part fracture of the proximal part of the humerus. Operative treatment. *J Bone Joint Surg Am.* 1986;68:1410-1414.

20. Neer CS 2nd. Displaced proximal humeral fractures. II. Treatment of three-part and four-part displacement. *J Bone Joint Surg Am.* 1970;52:1090-1103.
21. Stableforth PG. Four-part fractures of the neck of the humerus. *J Bone Joint Surg Br.* 1984;66:104-108.
22. Rose PS, Adams CR, Torchia ME, Jacofsky DJ, Haidukewych GG, Steinmann SP. Locking plate fixation for proximal humeral fractures: initial results with a new implant. *J Shoulder Elbow Surg.* 2007;16(2):202-207.
23. Joon Yub Kim, Jinho Lee, and Seong-Hun Kim. Comparison between MIPO and the deltopectoral approach with allogeneous fibular bone graft in proximal humeral fractures. *Clin Shoulder Elb.* 2020; 23: 136–143.
24. Bing Wang, Cheng Zhu, Ping Wang, Zi-Zheng Wu, Qian-Fa Zhang. Effect of primary neck-shaft angle after operation on the treatment of proximal humerus fracture by locking plate. *Zhongguo Gu Shang* 2018;25:31(9):794-798.
25. Jonathan Heath Thompson, Basem Attum, Andres Rodriguez-Buitrago, Kurt Yusi, Cesar Cereijo, William T Obrebsky. Open Reduction and Internal Fixation with a Locking Plate Via Deltopectoral Approach for the Treatment of Three and Four-Part and Proximal Humeral Fractures. *JBJS Essent Surg Tech.*2018; 8: 1-2.
26. Dominique M Rouleau, Frédéric Balg, Benoit Benoit, Stéphane Leduc, Michel Malo, François Vézina, et.al. Deltopectoral vs. deltoid split approach for proximal Humerus fracture fixation with locking plate: a prospective RAndomized study (HURA). *J Shoulder Elbow Surg.* 2020;29:2190-2199.