

Unusual Causes of Adnexal Masses in Early Reproductive Period

Erken Üreme Çağında Adneksial Kitlelerin Nadir Sebepleri

Dr. Erdin Ilter / Maltepe University, Faculty of Medicine, Department of Gynecology

Dr. Neşe Yener / Maltepe University, Faculty of Medicine, Department of Pathology

Dr. Aygen Celik / Maltepe University, Faculty of Medicine, Department of Gynecology

Dr. Tonguç Gündüz / Maltepe University, Faculty of Medicine, Department of Gynecology

Dr. Erdal Yücel / Maltepe University, Faculty of Medicine, Department of Gynecology

Dr. Berna Haliloğlu / Maltepe University, Faculty of Medicine, Department of Gynecology

Dr. Ahmet Midi / Maltepe University, Faculty of Medicine, Department of Pathology

Dr. Umit Ozekici / Maltepe University, Faculty of Medicine, Department of Gynecology

ÖZET

Üreme çağında tespit edilen ovaryan tümörler akıl karıştıracıdır. Bu yazıda üç ayrı tanıli vaka sunuyoruz; Overin immature teratomu (IT), overin primer peritoneal seröz papiller karsinomu (PSPC) ve metastatik ovaryan diffuz büyük B-hücreli Lenfoması. Overe ait IT sıklıkla solid, artmış alfa-fetoprotein değerleriyle birlikte görünen nadir bir tümördür. PSPC, normal büyüklükte overler, yaygın peritoneal karsinomatosis ve belirgin artmış CA12-5 değerleriyle birlikte olan hastalarda tanıda düşünülmesi gerekir. Lenfoma, CT'de çok sayıda büyümüş nodların füzyonu veya tek oldukça genişlemiş lenf nodlarını içeren solid kitleler olarak karşımıza çıkar. Lenfomalar en hızlı doubling zamanına sahip olduğundan radyolojik inceleme birkaç günde ilerleme gösterebilir ki bu bir ipucu olabilir. Özellikle nodal kitleler ile birlikte ovaryan kistler ovaryan metastazı olan lenfomayı düşündürür.

Anahtar kelimeler: Ovaryum ve tuba uterina hastalıkları; üreme

ABSTRACT

Ovarian tumors when detected in the reproductive period are challenging. We present three different cases diagnosed as an immature teratoma (IT) of ovary, a primary peritoneal serous papillary carcinoma (PSPC) and a metastatic ovarian diffuse large B-cell Lymphoma in the early reproductive period. IT of the ovary is an uncommon tumor; predominantly solid with increased serum alpha-fetoprotein levels may be associated with a greater likelihood. PSPC should be suggested as a diagnosis in patients with extensive peritoneal carcinomatosis, relatively normal sized ovaries, and a highly elevated serum CA-125 level. Lymphomas on CT may appear solid, include singular enlarged lymph nodes and fusion of multiple enlarged nodes. As lymphomas have fastest doubling time the radiologic evaluation may progress in few days and may be a clue for the diagnosis. Especially, ovarian cysts with nodal masses suggest a lymphoma with ovarian metastasis.

Key words: Adnexal Disease; Reproduction

Ovarian tumor which can be categorized into epithelial, germ cell, sex cord-stromal, or metastatic, are the sixth most common cancer in European women (5% of all cancers) (1).

These tumors when detected in the reproductive period are challenging. The nonepithelial ovarian cancer which include malignancies of germ cell, sex-cord-stromal cell origin, metastatic carcinomas, and a variety of extremely rare ovarian cancers (e.g., sarcomas, lipid cell tumors and lymphoma) represents most of the adolescent and reproductive malignant ovarian neoplasms (2).

We here present three different cases diagnosed as an immature teratoma (IT) of ovary, a primary peritoneal serous papillary carcinoma (PSPC) and a metastatic ovarian diffuse large B-cell Lymphoma in the early reproductive period.

Case 1

A 25 years old woman (G2,P2) was admitted with abdominal pain. Ultrasound and pelvic MRI revealed a semi-solid mass with the biggest size of 150x100mm. (Ca125:98 IU/ml, Ca19-9:100 IU/ml). At the laparotomy,

the right ovarian mass was resected. At the frozen section immature teratoma of the ovary was the first diagnosis. Since the tumor didn't extend beyond the left ovary, and the patient wanted a fertility sparing surgery, unilateral salpingooferection and full staging procedure were performed. The final pathologic diagnosis was Grade II astrocytoma and neuroblastoma arising in immature teratoma with negative lymph nodes, peritoneal washings and biopsies (stage Ia) (Figure 1). With the medical oncology consultation a three cycle of bleomycin, etoposide and cisplatin treatment was decided.

Case 2

A 27 years old woman (G1,P1) was admitted with a complaint of bilateral groin pain for a few months. Pelvic Computed Tomography (CT) showed a 39x30mm mass adjacent to the right ovary (Figure 2). The tumor markers were all in normal ranges. At the laparotomy, the uterus and both ovaries were normal. The mass fixed to the posterior isthmus part of the uterus in cul-de-sac was excised. Intraoperative pathology consultation reported mass as a tumor being at least borderline malignant serous papillary tumor. Then, full staging procedure was performed. The fact that the patient was a young woman of childbearing age, the operation was completed without any further invasive procedures.

Due to the final pathological diagnosis of primary peritoneal papillary serous carcinoma (PSPC) (Figure 3) with residual disease, second-look surgery was performed with a complete debulking surgery (total abdominal hysterectomy, bilateral salpingooferection, bilateral pelvic lymph node dissection, infracolic omentectomy, appendectomy and low anterior resection of colon). The tumor was reported to infiltrate the serosal surfaces of the rectal and sigmoidal wall. The patient, with an uneventful

recovery was transferred to medical oncology unit for chemotherapy treatment.

Case 3

A 26-year-old female patient (G1,P1) complaining of pelvic pain and distention with 8kg weight loss was admitted to our gynecology clinics. The ultrasonography and the abdominal MRI confirmed bilateral ovarian tumor with another solid 75x83mm mass just over the bifurcation of aorta just beneath the intestinal loops (Figure 4). At the laparotomy, biopsies from ovaries and the mesenteric mass resulted as lymphoma (Figure 5). The surgery was finished without any further process. The patient was transferred to medical oncology unit for chemotherapy treatment.

DISCUSSION

The challenging period for adnexal masses in reproductive period begins if the mass have malignancy criteria. US, is so far the first step to confirm the presence of a mass and to determine its organ of origin. Further radiological methods (CT, MRI) are useful for accurate and differential diagnosis. But the diagnosis of these suspicious pelvic masses ultimately requires an exploratory laparotomy (3).

IT of the ovary is an uncommon tumor; comprising less than 1% of teratomas of the ovary (4). Malignant transformation is uncommon and seen in approximately 2% of cases, usually in older women (most commonly squamous cell carcinoma 75% to 80%). Tumors of neuroepithelial origin are extremely rare in teratomas. We describe a case of ovarian IT with having both astrocytoma and neuroblastoma in the same tumor. IT may be solid or

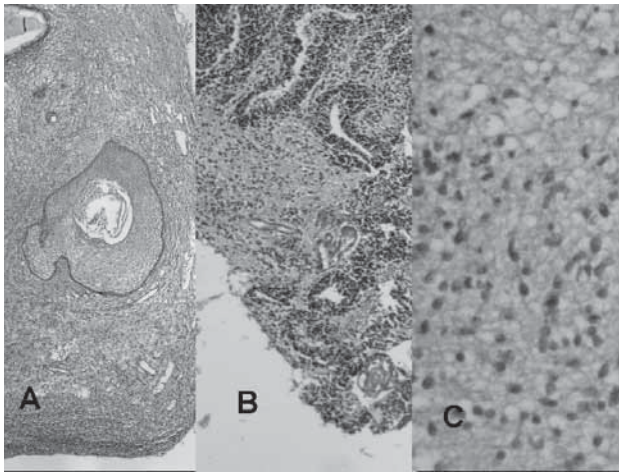


Figure 1.
1- Mature ectoderm (H&E X100)
2- Immature glial neuroplastic component (H&E X400)
3- Grade 2 glial (astrocytic) component (H&E X400)

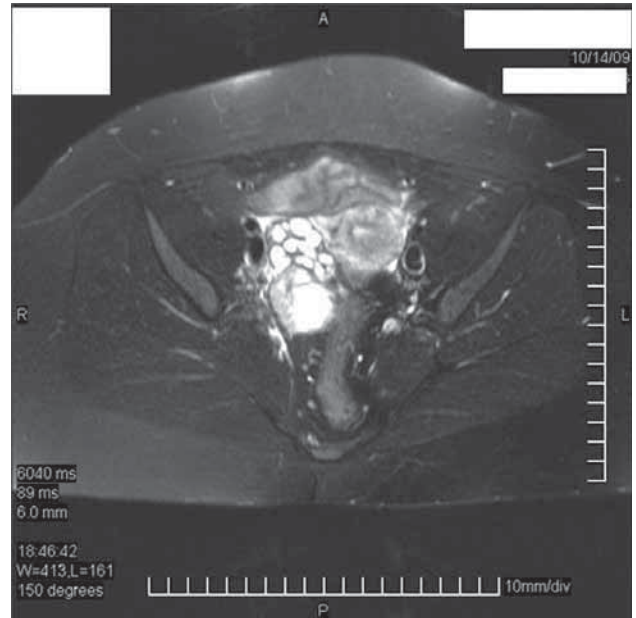


Figure 2.
39x30mm complex mass adjacent to the right ovary posterior to the uterus

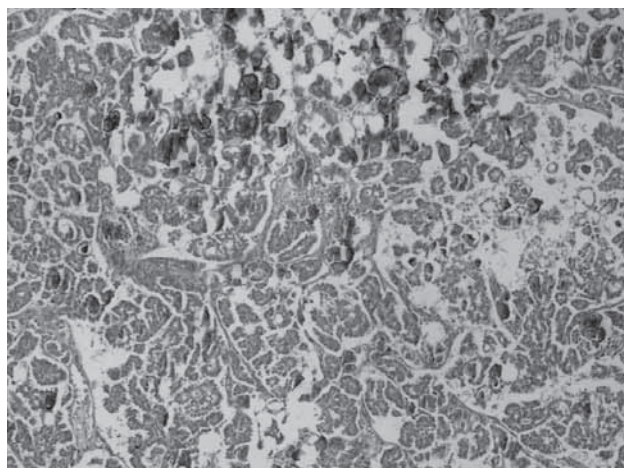


Figure 3.
Papillary structures with serous epithelia. (H&E X100)

cystic with solid components. These solid parts are usually recognized at CT and MR imaging. The existence of solid component can be sign of an immature teratoma, although mature teratomas sometimes have large solid parts. There is no complete diagnostic criterion for immature teratoma, although large, predominantly solid masses with increased serum alpha-fetoprotein levels may be associated with a greater likelihood (5,6).

PSPC have pathologic features closely resemble those of their ovarian counterparts (7). Some characteristics of CT of PSPC are reported as mesenteric or omental involvement, ascites, peritoneal thickening, extensive peritoneal calcification and normal-appearing ovaries (9-12). However some may show no sign of these criteria and have relatively large ovarian masses (8,9). The CA-125 antigen seems to be the most effective tumor marker for a primary peritoneal carcinoma (12). However, it should be noted that not all primary peritoneal carcinomas exhibit increasing levels of CA-125 (13). PSPC should be suggested as a diagnosis in patients with extensive peritoneal carcinomatosis, relatively normal sized ovaries, and a highly elevated serum CA-125 level.

Ovarian involvement by lymphoma may be the early manifestation of a systemic disease (14) or less commonly lymphoma may arise de novo in the ovary (15,16).

Lymphomas on CT may appear solitary, multiple-nodular or diffuse. Solitary mass includes singular enlarged lymph nodes and fusion of multiple enlarges nodes. The most frequently seen multiple-nodular type is diagnosed by enlarged lymph nodes with regional distribution. Both solitary and multiple-nodular types have clear margins. The CT features of diffuse type show diffuse but non-confluent enlarged lymph nodes in the mesenteric and retroperitoneal region with uniform density and cobblestone appearance. As lymphomas have fastest doubling time the radiologic evaluation may progress in few days and may be a clue for the diagnosis. Especially,

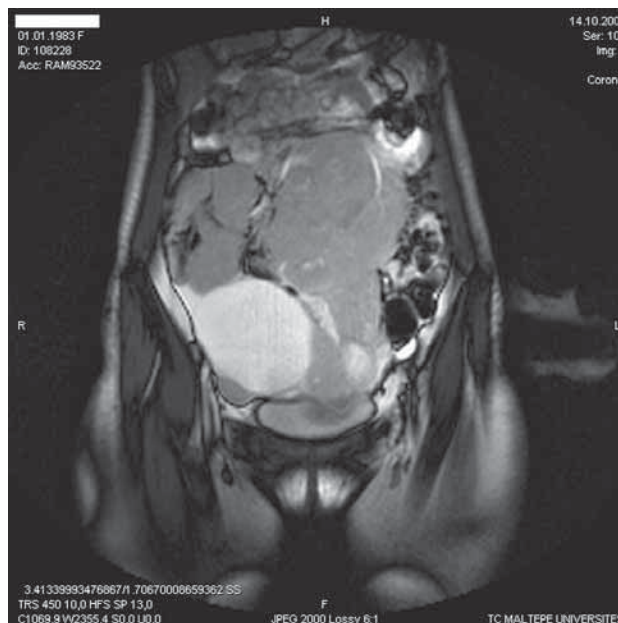


Figure 4.
Bilateral ovarian tumor with another solid 75x83mm mass just over the bifurcation of aorta

ovarian cysts with nodal masses suggest a lymphoma with ovarian metastasis (17-21).

MRI may also be a helpful for differential diagnosis. Ferrozzi et al (22) reported that the MRI findings of metastatic ovarian lymphoma included solid bilateral masses, which were low signal intensity on T1 weighted images and mildly high signal intensity on T2 weighted images. Lesions were homogeneous with mild to moderate contrast enhancement with intravenous gadolinium.

Adnexal masses at reproductive age have great importance. Preoperative evaluation has a key role in

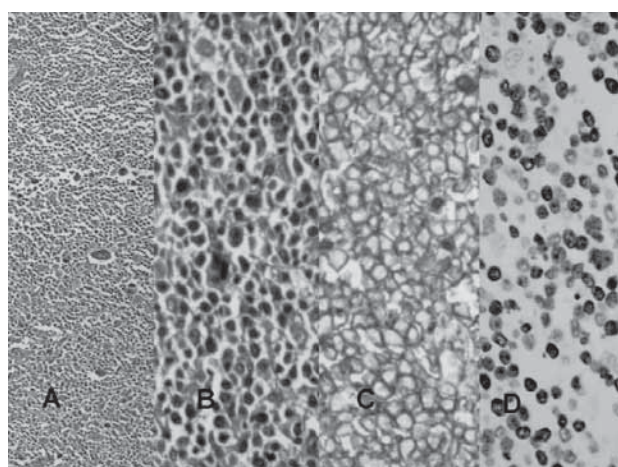


Figure 5.
1- Lymphoid infiltration , diffuse pattern (H&E X100)
2- Infiltration with centroblast and centrocytes (H&E X400)
3- CD20 staining of malign cells (X400)
4- High proliferation index with Ki-67 staining (X400)

differential diagnosis. All adnexal masses need further whole body physical examination. It should always be remembered that an ovarian tumor may be metastatic. Radiological evaluation especially CT and MRI may be helpful to differentiate the mass.

REFERENCES

1. Ferlay J, Bray F, Pisani P, Parkin DM. GLOBOCAN 2002: Cancer Incidence, Mortality and Prevalence Worldwide. IARC CancerBase No. 5, version 2.0., Lyon: IARC Press 2004
2. Di Saia P, Cresman WT. Clinical gynaecological oncology. USA: Mosby; 1997. p. 351–74.
3. Colombo N, Gorp T.V, Parma G, Amant F, Gatta G, Sessa C, et al. Ovarian cancer Crit Rev Oncol Hematol 2006;60:159–179
4. Talerman A. Germ cell tumors of the ovary. In: Kurman RJ editor. Blaustein's Pathology of the female genital tract. 5th ed. Springer. p.994
5. Sabaa L, Guerrierod S, Sulcis R, Virgilio B, Melis GB, Mallarinia G. Mature and immature ovarian teratomas: CT, US and MR imaging characteristics Eur J Radiol 2009;72:454–463
6. Çilesiz G.P, Çetin A, Tarlacı A, Ton Ö. Immature ovarian teratoma presenting with abnormal uterine bleeding. Türkiye Klinikleri J Gynecol Obst 2007;17:334-6
7. Clement PB. Diseases of the peritoneum. In: Kurman RJ editor. Blaustein's Pathology of the female genital tract. 5th ed. Springer. p.771
8. Bell DA, Scully RE. Serous borderline tumors of the peritoneum. Am J Surg Pathol 1990; 14:230-239.
9. Bloss JD, Liao SY, Buller RE, Manetta A, Berman ML, McMeekin S, et al. Extraovarian peritoneal serous papillary carcinoma: a case-control retrospective comparison to papillary adenocarcinoma of the ovary. *Gynecol Oncol*. 1993;50:347–351.
10. Stafford-Johnson DB, Bree RL, Francis IR, Korobkin M. CT appearance of primary papillary serous carcinoma of the peritoneum. *AJR* 1998;171:687–689
11. Chopra S, Laurie LR, Chintapalli KN, Valente PT, Dodd GD III. Primary serous carcinoma of the peritoneum: CT-pathologic correlation. *J Comput Assist Tomogr* 2000;24:395–399
12. Altaras MM, Aviram R, Cohen I, Cordoba M, Weiss E, Beyth Y. Primary peritoneal papillary serous adenocarcinoma: clinical and management aspects. *Gynecol Oncol*. 1991;40:230-236.
13. Karlan BY, Baldwin RL, Lopez-Luevanos E, Raffel LJ, Barbuto D, Narod S, et al. Peritoneal serous papillary carcinoma, a phenotypic variant of familial ovarian cancer: implications for ovarian cancer screening. *Am J Obstet Gynecol*. 1999;180:917-928.
14. Fox H, Langley FA, Govan AD, Hill AS, Bennett MH. Malignant lymphoma presenting as an ovarian tumour: a clinicopathological analysis of 34 cases. *Br J Obstet Gynaecol* 1988 Apr; 95(4):386-390
15. Elharroudi T, Ismaili N, Errihani H, Jalil A. Primary lymphoma of the ovary. *J Can Res Ther* 2008;4:195-196.
16. Crawshaw J, Sohaib AS, Wotherspoon A, Shepherd JH. Primary non-Hodgkin's Lymphoma of the ovaries: imaging findings. *Br J Radiol* 2007;80:155-157.
17. Vang R, Medeiros LJ, Warnke RA, Higgins JP, Deavers MT. Ovarian non-Hodgkin's lymphoma: A clinicopathologic study of eight primary cases. *Mod Pathol* 2001; 14(11):1093-1099.
18. d'Amore F, de Nully Brown P, Weisenberger D. Epidemiology of extranodal lymphomas. In: Cavalli F, Stein H, Zucca E, eds. Extranodal lymphomas, pathology and management. London: Informa Healthcare, 2008: 14-23.
19. Wu N, Liu Y, Lin D, Chen Y, Shi M. Abdominal and pelvic lymph nodes in non-Hodgkin lymphoma: the nodal distribution in Chinese patients. *Zhonghua Zhongliu Zazhi* 2002; 24: 580-584
20. Yu R.S, Zhang W.M, Liu Y.Q. CT diagnosis of 52 patients with lymphoma in abdominal lymph nodes *World J Gastroenterol* 2006;28; 12(48): 7869-7873
21. Dilek S, Ergün A, Ülgenalp I, Orhon E, Rabuçu R. Extranodal primary ovarian lymphoma. *Türkiye Klinikleri J Gynecol Obst* 1994;4:197-199
22. Ferrozzi F, Tognini G, Bova D, Zuccoli G. Non-Hodgkin's lymphomas of the ovaries: MR findings. *J Comput Assist Tomogr* 2000;24:416–420.